TOSHIBA MEDICAL

VISIONS

Magazine for Medical & Health Professionals | March 2017

Together, we complete the image.

Made For life

28

28

The 'made for life' philosophy prevails as Toshiba Medical's ongoing commitment to humanity. Read more on page 12.

VISIONS magazine is a publication of Toshiba Medical Europe and is offered free of charge to medical and health professionals. The magazine is published twice a year. Registration to access full, previously published, digital editions can be done via the web site: www.toshiba-medical.eu/visions. Toshiba Medical stores and uses personal data of the registration to send out the magazine and inform members about new developments. Members can customize preferences or opt-out, after registration, in the online VISIONS profile. VISIONS magazine is covering Toshiba Medical's European region and as such reflects products, technologies and services for this particular area. The mentioned products may not be available in other geographic regions. Please consult your Toshiba representative sales office in case of any questions. No part of this publication may be reproduced in whole or in part, stored in an automated storage and retrieval system or transmitted in any manner whatsoever without written permission of the publisher. VISIONS Magazine is not responsible for any inaccuracies in this publication.

News items and articles are announced firstly, as pre-publication, via the dedicated VISIONS LinkedIn Group: https://www.linkedin.com/groups/3698045. In this group you can actively participate in discussions about the content and future direction of the magazine. Follow us also on SlideShare: http://www.slideshare.net/toshibamedical.

Publisher
Toshiba Medical Systems Europe B.V.
Zilverstraat 1
NL-2718 RP Zoetermeer
Tel.: +31 79 368 92 22
Fax: +31 79 368 94 44
Web: www.toshiba-medical.eu
Email: marketing@toshiba-medical.eu

Editor-in-chief
Jack Hoogendoorn (jack.hoogendoorn@toshiba-medical.eu)

Editor
Jacqueline de Graaf (jacqueline.degraaf@toshiba-medical.eu)

Modality coordinators and reviewers
CT: Roy Irwan, Chloe Steveson
UL: Jeroen Uijttenhout
MR: Martin de Jong, Wolter de Graaf
X-Ray: Rene Degros

Design & Layout
Boerma Reclame (www.boermareclame.com)

Photography
Cojan van Toor (www.cojanvantoor.nl)

Printmanagement
Het Staat Gedrukt (www.hetstaatgedrukt.nl)

Text contributions and editing
The Creative Practice (www.thecreativepractice.com)

Subscription Service
www.toshiba-medical.eu/visions

ISSN 1617-2876

Follow us

Dear reader,

'Together, we complete the image' is the tagline of our new corporate campaign. A statement that could not have found a better moment to see 'the light of day' than right now, as its core message has everything to do with partnership and results.

At Toshiba Medical, we are proud to build partnerships and relationships that are based on transparency, trust and respect. Our commitment to progressive medical-, corporate-, academic- and community partnerships lies at the very heart of what we do and why we do it. Together as one, we strive to create industry-leading solutions that deliver an enriched quality of life.

'Together' obviously refers to the many different stakeholders of our company. For example, to our employees, who dedicate themselves daily to devising appropriate solutions and configurations for hospitals, clinics and patients.

And obviously, to our customers that use our systems and solutions in their everyday practice. They can rely on the best imaging quality with the least patient impact (e.g. radiation dose) and supreme patient comfort.

Last, but not least, to our new parent company, Canon, that ensures we will maintain the high standards that we are known for in the market and our ability to develop new innovative technologies and systems.

With all of the above in mind, the ***'Together, we complete the image'*** message is enriched, and expresses that we prefer to work hand-in-hand with our customers and partners to consider the complete picture, beyond imaging, in a manner that achieves better patient outcomes and, as such, contributes to life and living.

Kind regards,

Jack Hoogendoorn
Senior Manager Marketing
Toshiba Medical Systems Europe BV

8 Mark Holmshaw, Toshiba Medical's Vice President Marketing, Sales and Service is passionate about further strengthening and enhancing the companies' position in the healthcare industry

13 The new Vantage Galan 3T

26 Joost Roelofs, Dr. Lucia Kroft and Dr. Koos Geleijns explain how the new system enables them to integrate relatively new CT applications seamlessly into everyday clinical practice.

CONTENTS

43 Infinix-i Sky +
The world's fastest, most flexible angio suite.

50 The new generation architecture and advanced transducer technology provide an extraordinary experience with fast and easy workflow combined with superb imaging and clinical applications.

NEWS

Regional Collaboration Enhances State-of-the-Art MRI Capabilities in France

In a pioneering public-private association, more than 140 radiologists, 3 public hospitals and 14 clinics in the Gironde department in South West France have joined forces to purchase a state-of-the-art, Vantage Titan 3T Saturn Edition MRI system from Toshiba Medical Systems. The collaboration is the first of its kind in France. The Vantage Titan 3T MRI system purchased is also the first with a Saturn Gradient system to be installed in Europe.

Shared Technology

The Vantage Titan 3T Saturn Edition is a 3 Tesla, high magnetic field, imaging system that enables more precise diagnosis. Its advanced technological features will boost the high-end MRI capabilities of the area's health service significantly. Until now, the Gironde department had just one other 3 Tesla MRI, located at the Bordeaux University Hospital (CHU). In France there are 80 MR 3T in use and effectively 2 in this territory. And around 1,000 worldwide.

Health professionals from public hospitals in Arcachon, Langon and Libourne, 14 private hospitals, and more than 140 radiologists from private practices in Gironde formed a consortium to pool funds for the new machine and the construction of a brand new building for use for the new system at a private clinic in Pessac: a location selected due to its ease of access within the department. The group also agreed upon a system for efficient shared use of the machine between the local health centers.

"This innovation shows how effective collaboration between health professionals in public hospitals and private practitioners can be: acting as individual entities, we would never have got there," said Dr. Jean-Christophe Sananes, a Radiologist at two of the consortium's clinics, and one of the initiators of the project. "Each of the practitioner groups, hospitals and clinics holds an equal share in the new system."

With use of the new Vantage Titan 3T Saturn Edition smoothly introduced in Gironde on October 3, 2016, health professionals in other departments in France have already expressed an interest in setting up a similar collaboration.

Toshiba Medical Celebrates 10 Years of Area Detector CT



Described as 'a breakthrough CT system' back in 2007, Toshiba Medical introduced the world's very first dynamic volume CT scanner, The Aquilion ONE™. Driven by the clinical need for a volume scanner, the Aquilion ONE's unique Area Detector opened doors to new ways of medical imaging. Ten years later, Toshiba Medical is celebrating this memorable introduction and developed a marketing mix of campaign activities. One of the campaign activities is our Special edition of VISIONS magazine: 10 YEARS AHEAD, Area Detector CT. This VISIONS Special highlights personal experiences of Key Opinion Leaders and outlines Toshiba Medical's journey in Area Detector CT.

Visit the campaign webpages: **www.toshiba-medical.eu/eu/ct-campaign-10-years-ahead** and download the digital version of this VISIONS CT Special!

Toshiba Medical Systems Corporation announces completion of acquisition by Canon Inc.

As a result of the recent completion of the competition law process by Canon Inc. (Canon), Toshiba Medical Systems Corporation (Toshiba Medical) would like to announce that it has joined the Canon group as of today.

As a Canon group company, Toshiba Medical will build a synergistic relationship based on the strengths of both Canon and Toshiba Medical in order to facilitate and expand our healthcare business globally.

Toshiba Medical will retain its company name and brand for a certain period of time and will inform you when a new corporate name and brand are determined.

NEWS

Toshiba Medical Introduced its Newest Premium Women's Healthcare Solution – Aplio i-series – at ISUOG 2016

Toshiba Medical introduced its newest premium Ultrasound system for Women's Heath at the World Congress of Ultrasound in Obstetrics and Gynecology, which was held from September 25 - 28 2016 in Rome, Italy.

Introduction of the new Aplio i-series followed by kagami biraki, a traditional Japanese sake ceremony. From left to right: Yasuyuki Masakari and Akihiro Sano (Ultrasound Division Toshiba Medical Corp.), Christoph Simm (Ultrasound Division Toshiba Medical Europe), Dr. Antonia Testa (ISUOG 2016 congress chair), Kazuyoshi Umemoto (Japanese ambassador to Italy), Mark Holmshaw (Vice President Marketing, Sales and Service Toshiba Medical Europe)

Aplio™ i-series combines superior image quality with the most advanced clinical applications in a highly intuitive design. This system takes diagnostic confidence and clinical capabilities to a new level while increasing workflow and productivity. Aplio i-series is the result of Toshiba Medical's 50 years of dedication to Ultrasound and partnerships with leading obstetricians from around the world.

Christoph Simm, Ultrasound Business Unit Manager, Toshiba Medical Europe explains: "With the new Aplio i-series we are extending our product line to the very top end with unique imaging and processing performance, which is reflected in outstanding image quality, ease of use, and a fantastic potential for new applications. Together with the current Aplio 500/400/300 Platinum series and the Xario 200/100 Platinum series we are offering our customers a very rich spectrum of attractive ultrasound products in the field of OB/GYN."

The new iBeam-forming architecture provides enhanced image quality thanks to sharper, more homogenous ultrasonic beams. This further strengthens Toshiba Medical's leading position in 2D image quality, which is most important in first trimester scanning and early detection of abnormalities. Simplified controls, a visual guided user

interface and automated image optimization features help to boost productivity, even during the more complex examinations, without compromising on accuracy and precision.

Newly developed transducers for the Aplio i-series are setting a new standard for routine scanning and advanced prenatal diagnosis by utilizing intelligent Dynamic Micro-slicing (iDMS) in combination with new iBeam forming technology. According to Petra Labs, Clinical Market Manager Ultrasound Women's Health Care, Toshiba Medical Systems Europe, "New ultra-wide band transducers can cover with superior sensitivity, spatial and contrast resolution finest diagnostics from the earliest pregnancy to full term, while helping to reduce cost and increase efficiency".

Next to improving its existing 3D applications such as Luminance 4D and Fly Thru virtual endoscopy, Toshiba Medical offers two completely new volume scanning technologies on the new platform:

With Smart Sensor 3D obstetricians can use 2D transducers to reconstruct highly accurate 3D volumes, allowing precise measurements to be performed. ***Shadow Glass*** provides clinicians volumes that contain more information about internal structures in relation with tissue borders.
Toshiba Medical's unique Superb Micro-vascular Imaging (SMI) technology has been further advanced, providing more vascular detail in ultra-low velocity flow imaging to reveal minute vessels in fetus and mother, never seen before with ultrasound. Dr. Jader Cruz, Portugal emphasizes: "SMI is proving to be an important new tool during first trimester cardiac assessment. It gives more confidence when assessing the fetal heart in the first trimester, especially the outflow tracts." Dr. Danielle Tournarde, France added: "With Smart Fusion we can merge live ultrasound imaging with pre-acquired MRI data, making it easy to locate anomalies in complex anatomy quickly and safely."

With the introduction of Aplio i-series and Diamond Sponsorship at the ISUOG World Congress, Toshiba Medical aims to further expand its leading capabilities in Ultrasound imaging in Obstetrics and Gynecology. Toshiba Medical introduced two new premium systems for Women's Healthcare: Aplio i800 and Aplio i700.

Mark Holmshaw, Toshiba Medical's Vice President Marketing, Sales and Service

"It's all about People"

From Vision to Value

With an impressive track record in engineering, sales and management, Mark Holmshaw, Toshiba Medical's Vice President Marketing, Sales and Service is passionate about further strengthening and enhancing the companies' position in the healthcare industry. Partnership, innovation and clear communication are key in his strategy to drive the business forward.

You manage marketing, sales and service for Toshiba Medical. What does this role entail?
We look after around 50 countries, so my responsibility is effectively for all customer-facing opportunities around the three areas of sales, service and marketing. We manage a turnover of between €400 and €500 million per year. So it's both a significant responsibility and a challenge, but one that I enjoy and thrive on, thanks to the great support that I receive from my team and feedback from all personnel in the organization

What do you find most interesting about this role?
The job combines all of my skill sets. My background is actually from Service. I was originally an engineer at Toshiba Medical. Then, I moved from Service into the Sales environment. My current role allows me to combine all of the skills that I have learned in these areas that I find important – principally, the customer-facing elements. I also really enjoy dealing with people and it provides an opportunity to work extensively with internal- and external customers, forming bonds and relationships that utilize all the skill sets that I have developed over the years

What personal qualities do you have to draw on most in your job?
You need to be a great politician! Most of the role centers around problem-solving of some description. This requires understanding people and knowing how to deal with different types of people and situations. In addition, defining strategic direction is important, but I think the people skills are key - whether in defining strategy, defining direction, or solving problems - the same skill sets are utilized, because it's about aligning ideas, and a lot of that is around how you deal with people. It's the skill of aligning people, particularly when coming from different directions to actually encourage them to move in the same direction.

What are the biggest challenges that you face?
Language, regulatory issues, and managing expectations. Language - because we cover so many countries. Regulatory issues for the same reason. And managing expectations, because people have different perceptions and expectations of the same strategic direction. So, you can define a direction, but if you don't explain it correctly, then people's expectations vary considerably. It's really about clear communication. Communication is also a key issue in itself.

What makes your team stand out?
They're all specialists in their own right. I always think the key to a good team is having the right people in the right place. It sounds obvious, but it's true. People doing the job that they were trained to do is critical. I'm not a Marketer by trade, so it's important for me to have experts who understand the marketing world inside and out to advise me. It's a team effort at the end of the day. Within it are many different teams. The challenge is to bring everybody to the same standard, so that all the teams complement each other optimally. As we all know we are only as strong as the weakest link.

What surprises you most about the healthcare industry?
Sometimes, how we all in general try to overcomplicate rather than simplify. Certain issues in healthcare, such as the problems experienced in administrative healthcare systems due to increased winter pressures, come around time and time again, and yet never seem to be solved, resulting in long waiting queues to get a consult or treatment. Sometimes, I think that applying more common sense would help resolve many situations.

What inspires you?
People. Even if you are a professor in a leading teaching hospital, if your dustbin is not empty at the end of the day, when you come in the next morning, it's probably the first thing you notice and it can get your day off to a bad start. So from the cleaning person, who takes the trash out of the professor's office, to the professor himself, and everyone in between; it's all about people. We cannot survive as an organization, as a human race, without treating people appropriately and giving them the respect they deserve.

Do you have any role models?
My father actually was an important role model, particularly later in my life. He was a steel worker and my mother was an office worker. My father had an extremely tough job. He worked in the steel works and regularly came home with burns and other injuries from the hot metal he worked with daily. He had many health problems. He

"Communication is also a key issue in itself"

made me think about how I would like to be treated, if I were a patient. At the end of the process that we are involved with on a daily basis, there is someone's mother, father, sister, brother… the so called patient. With that in mind, it is good to see how, what we do, impacts many people's lives in a positive way. Although, of course, those diagnoses can sometimes unfortunately have a huge negative impact on patients' lives and the lives of their family. We have to be mindful that is what we do.

In terms of the professional world, I have a lot of respect for individuals like Sir Richard Branson - A real 'self-made' man, who really seems to stay connected to people and maintains humility and humanity. Another one, who I have been fortunate enough to meet, who actually inspires me from a different perspective is Sir Alex Ferguson. He's an individual who faced opposition, because of his association with a particular brand, but actually what that man is capable of is amazing. He now lectures at Harvard. The words he uses and the experience that he has gained, he now puts into practice to teach other people, who maybe didn't like him some time ago, but can now see the methodology that he used works. He is to date the most successful man in the history of football. So, he did something right!

What do you think are the three, globally most important innovations in medicine ever made?

1. Cross-sectional imaging devices, such as CT and MR. Although these are very different techniques, they are actually variations on a theme, and so I would combine. This combination of modalities provide a new opportunity to diagnose problems.
2. Penicillin, which was a huge breakthrough.
3. A cure for cancer – although this has not yet been discovered, we're working hard towards it.

How does Toshiba Medical's service differ from other companies?

We have a lot of technological advantages within our products, but the thing that sets us apart from all of the others is our after-sales care. People make the difference. We treat customers like people, not like a number. We want partnerships, not customer-vendor relationships.

How do you envisage diagnostic imaging in 20 years from now?

I think there will be a lot more automization, probably centered around Artificial Intelligence. Perhaps more widespread use of computerized diagnosis, which has already been introduced in a very small way, but I can envisage rapid growth. I think data from medical devices will be stored only in the cloud, or in the next generation version of the cloud. I think there will be more focus on utilization rates of products and everything will be much more data driven.

How do you see the role of companies, like Toshiba Medical, in this?

Diagnostic imaging will continue, I think, but will take on a different shape. As far as markets are concerned, Toshiba Medical is already beginning to embrace new markets and diversify slightly into biotechnology. For example, we now make Ebola testing kits that are currently used in Africa.

We must keep up with technology. I don't think we can do that in an organic way, because big companies won't be able to survive purely through organic growth alone. The 'millennial generation" are key in driving the future of healthcare. We need to seek out promising start-ups in the healthcare industry, who can provide next generation programming and product evolution, because they understand today's market. I don't think that recruiting

that type of person in numbers will be enough, because of the inevitable inertia of big companies. We need young companies, who are not constrained by 'big company mentality', to ensure that we retain our agility and adaptability.

Toshiba Medical has also become the leader in Elite Sports Medicine Imaging. Why was this direction chosen?

Indeed we have a significant Elite Sports Medicine Program. Almost five years ago, we were fortunate enough to be selected as the medical systems partner for Manchester United and since then, we have also been selected as the medical systems partner for FC Barcelona and for REAL Madrid. We do have other areas of sports in which we are involved and in many different countries. So we have developed an Elite Sports Medicine Program, through which, we can offer our expertise and knowledge. Sport in general involves a huge amount of investment in people, nutrition and sport sciences, but diagnostic capabilities, are normally outsourced. This can compromise confidentiality, sometimes endangering the player and club's long-term reputation. We can offer the opportunity for instant diagnosis and confidentiality, also this will aid significantly in the future in rehabilitation of high value club assets (otherwise known as people).

How does this relate to the general public?

We also have an association with an organization called the AWRC - the Advanced Wellness Research Centre, in Sheffield, UK, which has been set-up through Olympic Legacy funding from the 2012 London Olympics. Its focus is the wellness of the general public around things like (for example) diabetes prevention, the wellness agenda, and how can you get people involved in more exercise. Through projects like this, many outcomes from the Elite Sports Medicine Program are transferred down into the general public. One of the ideas is to provide a gym membership for a period of time to treat for example back pain, instead of a prescription for painkillers. With imaging facilities available within the sports center, someone would design a one-month exercise program to assist the condition, and then after a month, the participant is re-scanned to see if the program helped. It's about combining the effects of reducing medicine, increasing exercise and just improving overall wellness of the general population. The AWRC is based in Sheffield, which represents about 1% of the population in the UK, as a test bed, but provides a significant enough population base, to see if the results could be used on a national basis.

Could you update us on the takeover by Canon? What will it mean for customers?

I am delighted that Toshiba Medical will be part of the Canon family. I think that the Canon brand will bring us a lot more credibility and we already received quite some positive feedback from our customer base. It's difficult to be able to quantify what will happen in the next few months, because we don't know at this moment in time, but I am generally pleased that we are part of the Canon Family. Our people will not change; we anticipate that our organization will become stronger.

Mark Holmshaw has 30 years experience in the medical imaging industry. He joined Toshiba Medical as Service engineer in 1991 moving forward to Sales Manager North of England and Scotland in the UK in 1996, becoming Senior Manager X-Ray in 2010, before being appointed as Vice President Sales, Marketing and Service Europe in 2012.

TOSHIBA MEDICAL

Together, we complete the image.

Made For life

Made for Life: Together, we complete the image.

Toshiba Medical is rearming its commitment to its Made for Life philosophy and launching a new theme and advertising campaign called "Together, we complete the image".

This campaign supports our Made for Life philosophy by focusing on our tradition of customer collaboration, developing products that are made for clinicians, patients and partnerships.

At Toshiba Medical, we listen to customers to truly understand their needs in imaging and beyond. Our goal is to work hand-in-hand with our partners to deliver flexible solutions that not only meet their needs but deliver optimal health opportunities for patients.

Together, we complete the image.

XR/VL: **Together, we make optimal workflow possible**
CT: **Together, we save time**
MR: **Together, we put your patients at ease**
UL: **Together, we help you see more**
HII: **Health informatics offers true enterprise interoperability**






Toshiba proudly welcomes the newest member of the Vantage family

The new Vantage Galan 3T



"With its perfectly balanced hardware and software package, the Vantage Galan™ 3T is impressive. Its compact design and low space requirement were important factors for me in making the decision to purchase."

Dr. Clemens Roznowicz,
Marienhospital Brühl, and Sana Clinic in Hürth, Germany.

Vantage Galan 3T

Vantage **Galan** *3T*

At first glance, the most impressive feature of the new Toshiba Vantage Galan 3T is its low space requirement of only 27 m2. However, as is usually the case with Toshiba systems, the Galan 3T's real talent lies hidden behind its slim, outer shell. Firstly, it scores exceptionally highly in energy-saving and, with the lowest electricity consumption, ranks top of the range among 3 Tesla MRI scanners. The low power input of only 70 kVA means that the running costs are considerably lower than similar 3 Tesla systems.

Inside the new Galan 3T, more efficient components, such as the improved gradient coils in Saturn quality, ensure top performance capacity with diagnostic accuracy and the highest standard of image quality - despite its reduced energy consumption. The system works with an improved version of the 'tried and trusted', Vantage Series matrix coil concept and new, second-generation, ATLAS coils. They are particularly well-adapted to local anatomy, but can also be combined when examining larger areas.

EXCELLENT IMAGING IN WHOLE BODY SCANS

In imaging, the Galan 3T is a symbiosis combining wide coverage (max. 50 x 50 x 205 cm) and visualization of the smallest details, by virtue of up to 128 HF channels. Combining active- and passive shimming, the compact and light magnet achieves a very stable magnetic field with a high degree of homogeneity. This ensures excellent imaging in whole body scans. Furthermore, the outstanding homogeneity in the large cylindrical field of view (50 x 50 x 45 cm) ensures very high accuracy of detail, even in the off-center field of view (e.g. shoulder and full abdomen). At the same time, this provides excellent fat-water separation; spectral fat saturation is of extraordinary quality, even at the edges of the field of view. As a result, the Galan 3T achieves outstanding measurements in spectroscopic scans. In addition, new RF technology, combined with the Saturn gradients, improves signal-noise ratio by up to 20%.

GENEROUS GANTRY APERTURE AND LOW NOISE EXPOSURE

Patient comfort is a high priority at Toshiba - with the new Vantage Galan 3T, this includes not only the generous gantry aperture of 71 cm, but also even lower exposure to noise during the scan. Through mechanical acoustic decoupling, Toshiba's patented Pianissimo technology reduces the gradient sounds in all sequences in- and around the MRI. This means that scanning with the Galan 3T is more 'patient-friendly' and the scanner is easier to operate. The optional Pianissimo Zen technology goes even further: This new technique developed by Toshiba ensures that the sound in sequences such as mUTE and FASE DWI, is reduced by up to 95 percent.

4D MRA of the cerebral arteries

Overview of savings potential

- Power input 70 kVA → full 3T performance at power input values of the 1.5T class.
- Continuous noise reduction → no more need for expensive soundproofing at the HF cage.
- True zero boil-off (4K cooling system) → no helium consumption in normal operation, operating costs are reduced.
- Low space requirement of only 27 m^2 → more room for the operating or changing rooms, for example, and lower HF cage investment.
- Quick installation → in only nine days.
- Automatic adjustment of energy consumption → ECO mode reduces energy costs.

"Close cooperation with Toshiba and the personal support that I have received in terms of service and application made it very easy for me to decide on the Galan 3T."

Dr. Clemens Roznowicz

Another highlight for patients is the MRI theatre function: Thanks to the latest projection technology, the tunnel can be used for visual animations during the MRI scan; this feature is also very useful to the functional MRI. Children can even watch their favorite film during scanning, which makes lying still much easier.

SIMPLIFIED SCAN PROCESSES WITH M-POWER INTERFACE

With its sophisticated options, the 3 Tesla Vantage Galan MRI Scanner fits perfectly into routine scanning work. Toshiba's M-Power user-interface considerably simplifies scanning processes, including evaluation, and guarantees ease-of-operation. In addition to the generous standard features, such as 3D post-processing, image fusion and much more, many extensive image processing and post-processing packages are available. These include Olea Nova+ (drastically reduces measurement time), which extends the spectrum of imaging with the Vantage Galan 3T even further. New sequences are available, e.g. for coronary imaging without CM, 4D MRA of the brain and many other examinations.

Thanks to predefined, 'follow me' instructions, less experienced staff are also able to operate the Vantage Galan 3T reliably. Automatic recognition of anatomical structures and autonomous positioning of specified alignments provide additional assistance with this. This pays off, not least in efficiency. For example, cardiac scan times can be reduced by up to 10 minutes.

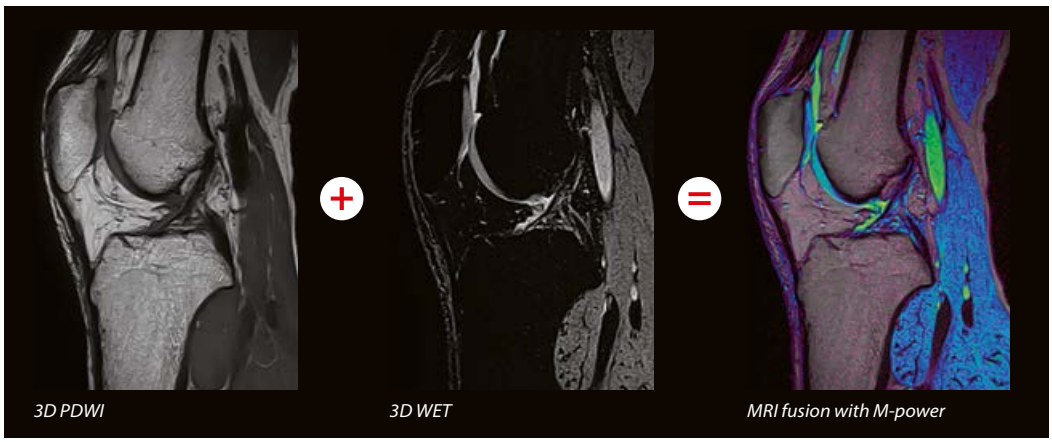

3D PDWI *3D WET* *MRI fusion with M-power*

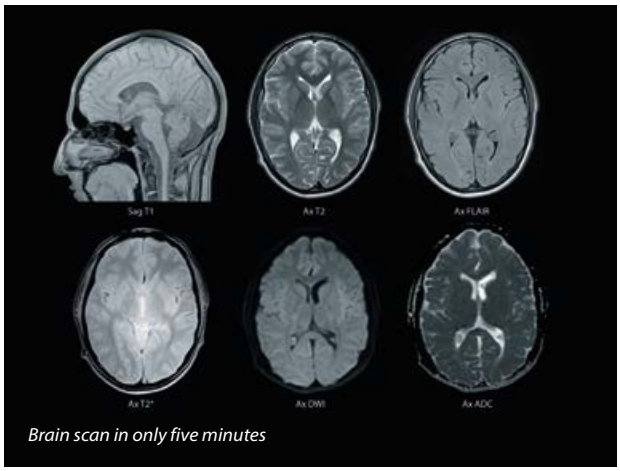

Brain scan in only five minutes

New, low-dose, 80-row Aquilion Lightning SP CT System

World Debut at Bielefeld Hospital – So much more than just a new CT Machine

In the field of radiology, both doctors and patients justifiably have high expectations. The doctor expects the highest diagnostic standards, maximum availability and optimum efficiency from the technology. All this, is required at excellent value for money, for the purchaser, who expects to invest in technology without having to first extensively shop around or compromise on finances. These expectations are now fulfilled in the Radiology Department of Bielefeld Hospital, in Germany, with the introduction of a new, low-dose, 80-row Aquilion Lightning™ SP CT system from Toshiba Medical.

Aquilion Lightning: world's first 80-row low-dose routine scanner

Prof. Dr. Hans-Björn Gehl,
Head of the Institute for Diagnostic Radiology, Bielefeld Hospital

"Our demand on the new CT is very high...When we commissioned the CT, we knew that it was able to fulfil all our requirements."

In September 2016, the first low-dose, 80-row Aquilion Lightning SP CT system in the world was installed in the Department, which is headed by Professor Hans-Björn Gehl. Since then, this latest addition to Toshiba Medical's Aquilion Lightning range, has delivered beyond expectations on a full range of routine examinations - The 'SP' stands for 'Superior Performance'.

"Demand on the system is very high. We want every patient to have a fast and painless examination and a reliable result, in the shortest time possible. Hence we chose for the latest technology and iterative dose reduction," said Professor Gehl. "When we commissioned the Aquilion Lightning SP CT system, we knew that it would be able to fulfill all our requirements."

THE LATEST LOW-DOSE DETECTOR AND RECONSTRUCTION TECHNOLOGY

The low-dose Aquilion Lightning SP combines a range of technologies that originate from high-end CT development, including both the acquisition of data and reconstruction of images.

Patients are scanned using the 80-row, low-dose PUREViSION Detector, which possesses a higher light output than its previous models. The new detector enables doctors to work with up to a 40% lower X-Ray dose and less contrast medium.

"Immediately after acquisition, the reconstruction of data from the Aquilion Lighting SP begins automatically at 50 images per second," remarked Professor Gehl. "This high reconstruction speed shortens the amount of time until images are ready for review."

Exceptional performance is achieved by incorporation of the mathematically complex, raw- and image data-based iterative dose reduction, AIDR 3D Enhanced, which reduces the dose by up to 75%. A further reduction in dose is provided by the active collimator – a screen that blocks out x-rays at the start and end of the scan to limit the radiation dose to only what is required for image reconstruction. This ensures that patients are scanned at the lowest possible dose.

"While we could meet all reference values previously on our old machine, the Aquilion Lightning SP regularly requires a dose of one third below the reference," added Professor Gehl.

PATIENT-FRIENDLY EXAMINATIONS USING LESS CONTRAST MEDIUM

The Aquilion Lightning SP provides a good balance. On one hand, the patient receives the lowest possible dose and less contrast medium are required for a reliable result. On the other hand, the image is ready for diagnosis in a shorter time; waiting times are, therefore, reduced, and the satisfaction of all those involved is increased.

In addition, the Aquilion Lightning SP has providing a calming, wide open space for a better patient experience. Radiologists also benefit from the additional space, as complex, image-guided interventions can be carried out more easily. The acquisition of the 80-row CT is remarkably fast, which is particularly important in scans of the lungs, as patients with pulmonary disease may not be able to hold their breath for a very long time, if at all. In emergency cases, the Aquilion Lightning SP's extended table allows whole body scanning without the need to move the patient.

BRILLIANT IMAGE QUALITY USING A MINIMAL DOSE

Metal implants such as those in the knee and hip as well as vascular stents create artifacts that can impede diagnosis. The Aquilion Lightning SP relies on SEMAR (Single Energy Metal Artefact Reduction), which analyses the raw data acquired, in order to extract any metal artefacts. It enables visualization of areas close to the many (metallic) implants that patients often have nowadays. Particularly

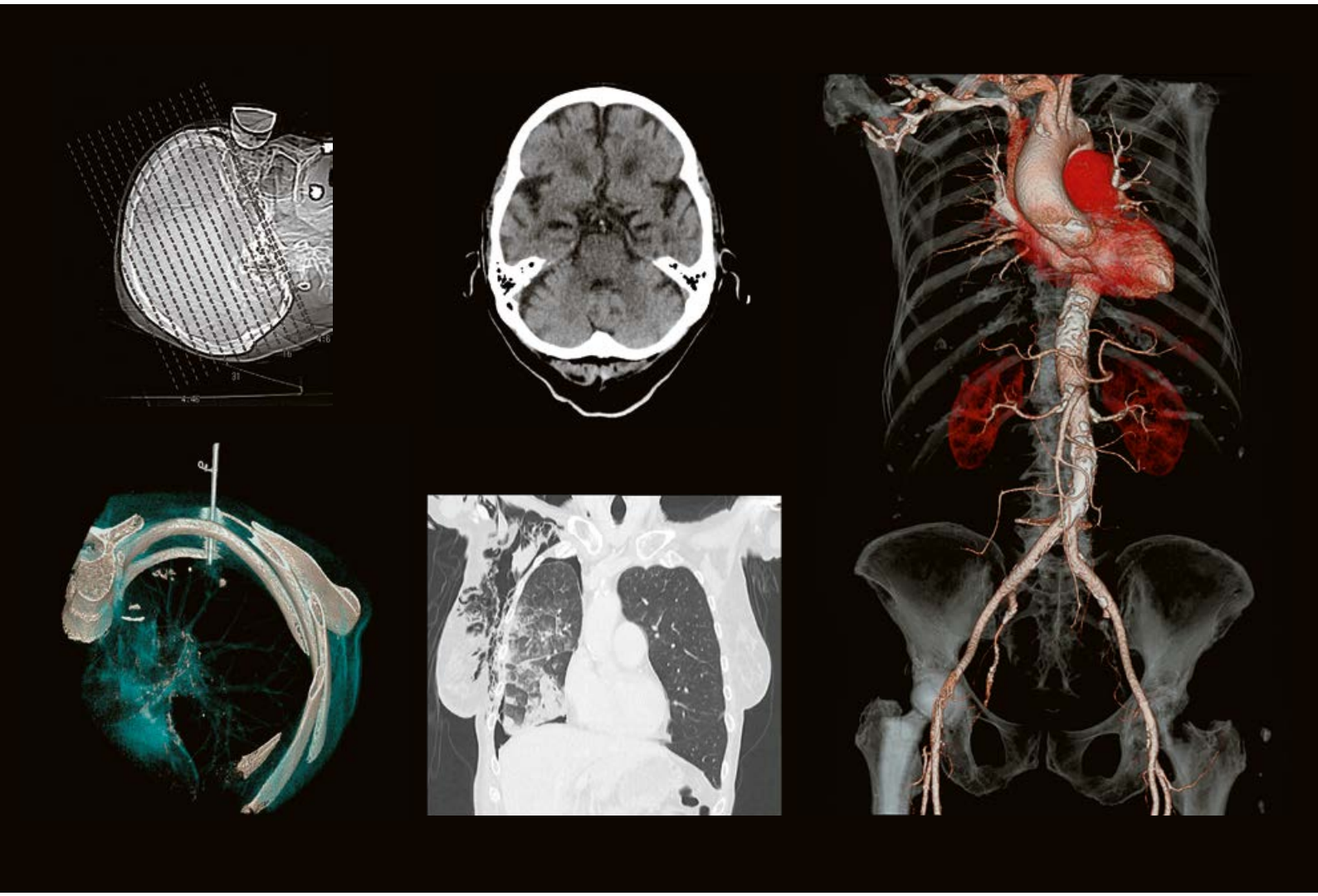

Prof. Dr. Hans-Björn Gehl

"Thanks to SEMAR, Toshiba offers us very effective metal artefact suppression, which enables the implant as well as the surrounding tissue to be better visualised many times over".

helpful is the fact that SEMAR images require no additional scans, but rather can be reconstructed simply after the scan.

"Through SEMAR, Toshiba Medical offers us very effective metal artefact suppression, which enables the implant, as well as the surrounding tissue to be better visualized" explained Professor Gehl. "Neighboring structures, like vessels in angiograms can be visualized without difficulties. Pathology in the direct vicinity of metallic implants can now be observed, which was previously impossible. SEMAR is particularly appreciated by the surgeons from our large Orthopedic Department. The 3D-renderings enhance clarity in deciding exactly how to operate."

HIGH ENERGY-EFFICIENCY

Thanks to the high-performance technology used, the new Aquilion Lightning SP is a particularly energy-efficient routine CT. The iterative dose reduction provides an important basis for this. As the new CT machine functions with a very low dose, the X-Ray tubes require less mA (tube current). Cooling and waiting times are also a thing of the past. AIDR 3D is a major factor in obtaining energy efficiency – shorter examination times per patient enable a higher level of performance and, therefore, directly affect the cost-effectiveness of the system and the comfort of patients.

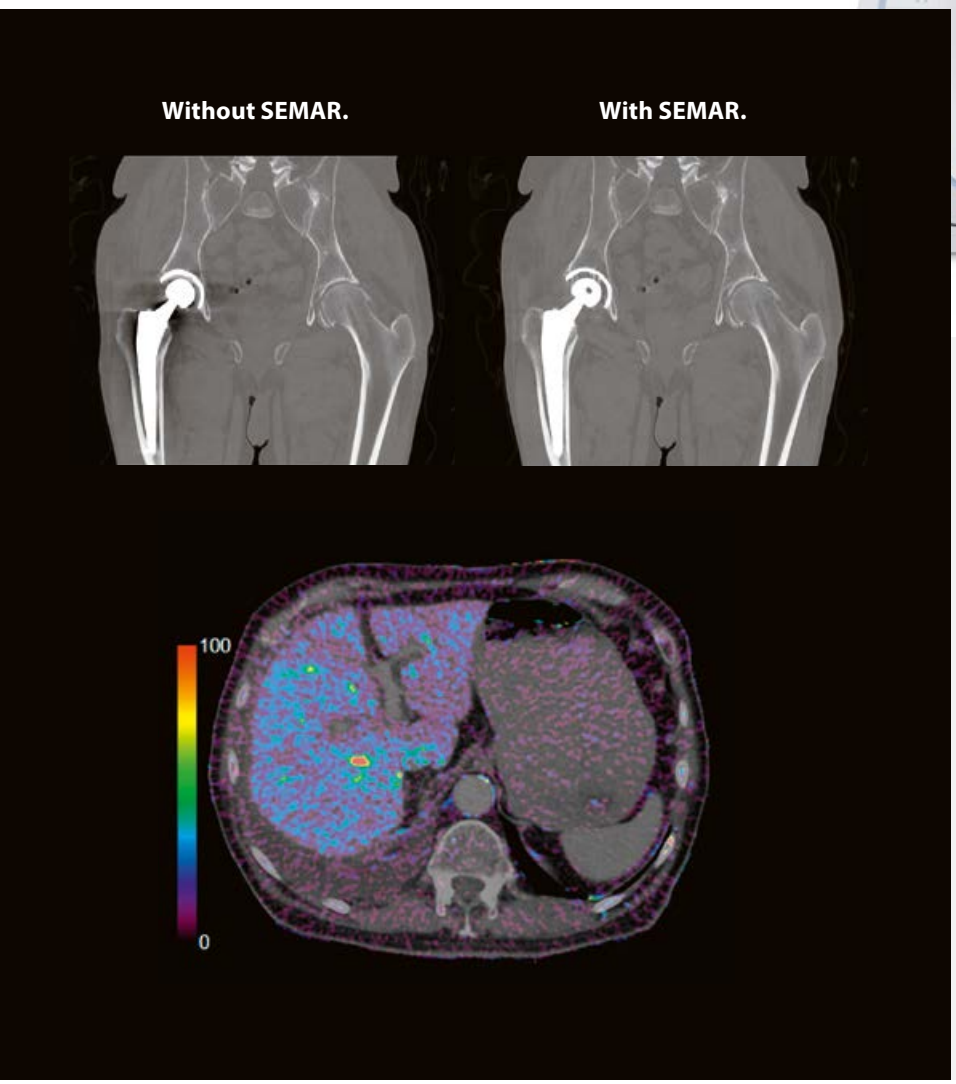

Bielefeld Hospital, Germany

Bielefeld Hospital, located in Bielefeld, in the North-Rhine Westphalia, in Germany, is a medical health center that aspires to the highest quality standards. Its utmost priority is the provision of the best medical- and nursing care and patient satisfaction. Reflecting its motto: "Our expertise for your health," Bielefeld Hospital stands for patient-oriented and modern, high-performance medicine. With more than 2,600 qualified employees, it ensures round-the-clock care for patients, every day of the year, at three sites: Klinikum Bielefeld Mitte, Klinikum Bielefeld Rosenhöhe and Klinikum Halle/Westfalen. With more than 1,100 beds, the Hospital's specialist departments and institutes treat more than 50,000 inpatients, and over 90,000 outpatients, per year.

Bielefeld Hospital has established an excellent reputation that constantly improves. It is considered as a significant health partner for people in the region.

Source: Prof. Dr. Hans-Björn Gehl, Bielefeld Hospital.

EASY-TO-USE

Fast adaption of radiographers to the CT machine's new software-interface enabled the Technicians at Bielefeld Hospital to start using the new system very soon after installation.

"After having already trained nine of our Radiographers, they all seem to prefer the 'new machine', because of its easier handling. This is particularly important, considering that 35 patients are scanned in an eight hour shift here," said Professor Gehl.

FUTURE-PROOFING AND EXPANDABILITY ARE PARTICULARLY IMPORTANT

The scope of innovations available is impressive. This is one of Toshiba Medical's biggest strengths: reacting to customer needs with a full understanding of the growing demands on the user. The Aquilion Lightning SP is, therefore, scalable in a particularly flexible manner. The user can compare their individual system using a comprehensive range of innovative software, and extend or upgrade as required. New software can often be released initially as a trial to collate experiences and to obtain the opinion of colleagues and referring doctors, for example, prior to permanent installation.

LANDMARK INTRODUCTION

The first installation of a Toshiba Medical Aquilion Lightning SP CT in the world took place in Germany for good reason. The legal stipulations and medical requirements for image quality and dose reduction are particularly high in Germany, many CT users from across the world, therefore, observe the German radiology sector and seek to exchange views with those involved in it, because what is tried and tested and implemented in Germany, may also be successful in many other countries.

Ultrasound in modern sports medicine

Powerful, versatile and intelligent are the attributes that the Xario™ 200 ultrasound machine and top athletes have in common. The Xario 200 meets diagnostic requirements with extreme versatility, highly flexible work processes and consistently superior image quality for an exceptionally appealing price. This makes it a perfect fit in an environment dominated by superlatives: the Red Bull Football and Ice Hockey Academy in Salzburg-Liefering.

Dr. Thomas Hoffelner, Trauma Surgeon and Team Doctor for Red Bull Salzburg and Dr. Jörg Eichinger, Internist and Deputy Medical Director of the EMCO Private Clinic.

Red Bull sponsors various football and ice hockey clubs. To promote talented young athletes in these two sports, Europe's most state-of-the-art athletic academy was opened in Salzburg-Liefering two years ago. Some 400 young athletes are being trained and fostered at the Academy, the site of a former harness racing track. The Red Bull Football and Ice Hockey Academy can only be described using superlatives: In only 21 months' time, seven football fields, an indoor arena and two ice rinks were built on the 100,000 square meter property. There is approximately one instructor for every 10 young athletes. The athletes are housed dormitory style, in 88 double rooms. An activity park, ice hockey dry training centre, multi-purpose hall, body-building gym and regeneration area are all available to the athletes around the clock.

IMAGING IN MODERN SPORTS MEDICINE

Two team doctors, affectionately called "Doc" by their charges, look after the players' physical well-being and handle the performance diagnostics. They are assisted in this not only by a team of massage and physical therapists but also by the Xario 200. "Those who deal in-depth with the technical possibilities of ultrasound know that near MRI quality can be achieved with it for many applications," agree team doctors Dr. Jörg Eichinger, cardiologist and Dr. Thomas Hoffelner, injury and sports traumatologist. "Muscle fibre injuries are practically our daily bread and can be perfectly covered with the Xario 200," says Dr. Hoffelner, expert in diagnosing and treating the entire musculoskeletal system, praising the device. Dr. Eichinger knows the Xario 200 from his practice: "I had

Red Bull Football and Ice Hockey Academy

Dr. Jörg Eichinger

"When an injury occurs, we can very quickly determine whether and which treatment is needed."

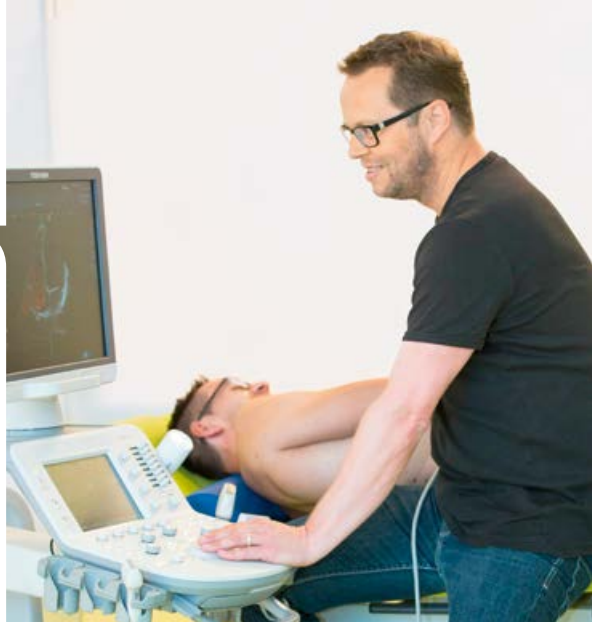

good experiences with it. Here at the Red Bull Football and Ice Hockey Academy, we acquired additional ultrasound machines for soft tissue which I had not used before for my cardiology patients. Because using the device is easy and intuitive, learning new techniques is not difficult," says Dr. Eichinger. And the cardiologist knows what he's talking about, since he tested six different devices by various manufacturers and ultimately chose the Xario 200 by Toshiba.

Team Doctor Dr. Hoffelner has noted major differences in terms of display: "We still have a predecessor model at the clinic, and the difference is quite noticeable. Precision Imaging and ApliPure™+ produce exceptionally clear images that show each individual lesion, clearly demarcated," says the sports traumatologist, adding: "For our applications when examining our players, it's important for the results of the exams to be accurate and available very quickly. We can use ultrasound for everything from cardiac problems to the stomach to the lower leg muscles. QuickScan automatically optimises the image with a simple push of a button, which not only saves time but also allows for uninterrupted, seamless work processes."

EASY DOCUMENTATION

The fitness status of the football and ice hockey players is documented multiple times during the performance diagnosis. "Saving the various images that are available with a push of a button is necessary in order to obtain reference values. For muscle injuries, in particular, it´s important to see the images side by side", says Dr. Hoffelner. Once per year, all the athletes of the Red Bull Football and Ice Hockey Academy undergo an medical examination, and the football and ice hockey A-teams have additional exams if they have acute symptoms. "Before contract conclusion, all new athletes come in for routine fitness checks, which also includes a heart ultrasound," says Dr. Eichinger. But it's during the matches that the Xario 200 really proves its worth - in "real time": "When an injury occurs, we can very quickly determine whether and which treatment is needed. For young players, especially, we're trying as much as possible to use diagnostic means that avoid radiation exposure," both doctors agree. It's clear the Xario 200 is in the lead 1:0!

Xario 200

Dr. Thomas Hoffelner

"Muscle fibre injuries are practically our daily business and can be ideally covered with the Xario 200."

High spatial resolution at short acquisition times

With 16ch Tx/Rx Knee SPEEDER coil

Dr. Matthew Bastian-Jordan, MBBS, BSc [1], Mr. Alastair Collett [2]

Matthew Bastian-Jordan

"The new 16ch Tx/Rx Knee SPEEDER coil is consistently delivering great image quality across a diverse range of patients. Combined with the Saturn Gradient Technology, we are achieving high spatial resolution without the need to increase acquisition times."

"Patients are finding the coil comfortable, it enables them to remain still for the duration of the scan. Along with the Transmit/Receive technology of the coil, the images that we are able to produce are sharper and allow for the easier visualisation of smaller and more subtle pathological changes."

Dr Matthew Bastian-Jordan, MBBS, BSc, FRANZCR

Alastair Collett

"We're getting some great image quality from the new 16ch Knee coil. The set-up times are greatly reduced and increases throughput. The coil utilises SPEEDER technology for all directions which enhances clinical value with higher spatial and temporal resolution. Moreover, the coil delivers excellent homogeneity that provides robust fat saturation."

Mr. Alastair Collett, the Chief MRI Technologist at QEII

[1] *Clinical Experience: fellowship in MSK with Queensland X-Ray and a fellowship in Abdominal and Cross Sectional Imaging through the Schulich school of Medicine and Dentistry, Western University in London, Ontario, Canada. Currently holds an adjunct professor position with Western University.*

[2] *Chief MRI Technologist at QEII*

Queensland X-Ray forms part of Sonic Healthcare, an Australian healthcare company focused on delivering medical excellence in radiology, pathology, general practice and occupational medicine.

Headquartered in Sydney, Australia, Sonic Healthcare is an ASX Top 50 company that has grown to become one of the world's leading healthcare providers, with an emphasis on medically-led decision making across all of its divisions and individual companies.

With practices throughout Australia, New Zealand, the United Kingdom, Germany, Switzerland, Belgium, Ireland and the USA, Sonic Healthcare employs over 14,000 Australians, and 30,000 staff worldwide.

Case 1: MRI of Left Knee

Patient History:
26 y/o, Work injury. Past lateral meniscectomy x 2. Some instability. No locking. Swelling+.

Technique and Parameters:
PD, PD FS, and T2 FS sequences of the left knee were performed.

FINDINGS
These sagittal acquisitions demonstrate an undisplaced multi directional tear through the posterior horn and an oblique tear through the anterior horn of the lateral meniscus. Minimal focal partial thickness chondral fissuring is noted anteriorly on the lateral femoral condyle.

	PD FS	T2 FS	PD
TR [ms]	2985	5118	2809
TE [ms]	27	81	28.5
Matrix	336	336	432
Spatial Resolution [mm]	0.4 x 0.4	0.4 x 0.4	0.4 x 0.3
Slice Thickness [mm]	3.2	3.2	3.2
Scan Time [min]	2:57	2:37	2:32

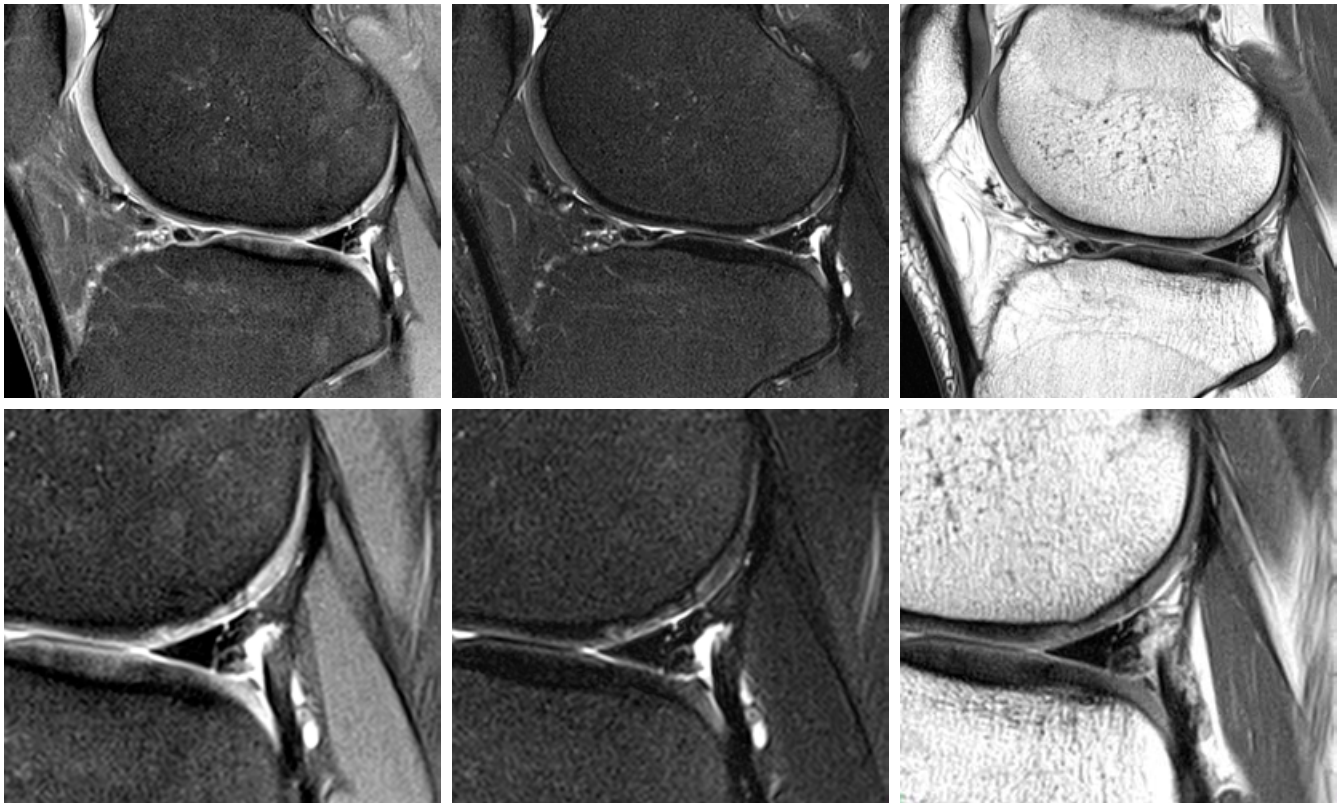

PD FS *T2 FS* *PD*

The results in this document are the findings of the author. Clinical outcomes may vary dependent upon clinical use and environment.

Case 2: MRI of Left Knee

Patient History:
39 y/o, Assess tibial tubercle at patellar tendon insertion.

Technique and Parameters:
3 plane PD FS, sagittal PD, 3T platform.

FINDINGS

Marked tibial tendinopathy distally persists with a fairly large intersitial tear noted. It suggests there is partial resolution of this focal patellar tendinopathy. There is a large delaminating tear present as seen previously in the depth of the trochlear groove. Within the medial compartment, there is a little complex signal within the body. Within the lateral compartment the meniscus is intact as are chondral surfaces. A quite marked patellar tendinopathy persists. There is a large chondral defect in the depth of the trochlear groove and the trunctation of the body of the medial meniscus is stable.

	PD Co FS	PD sg FS	PD Sg	PD Ax FS
TR [ms]	3235	3266	3044	4063
TE [ms]	28.5	30	38.5	30
Matrix	352	336	432	400
Spatial Resolution [mm]	0.4 x 0.4	0.4 x 0.4	0.4 x 0.3	0.4 x 0.4
Slice Thickness [mm]	3.0	3.2	3.2	3.3
Scan Time [min]	2:48	3:16	3:15	3:27

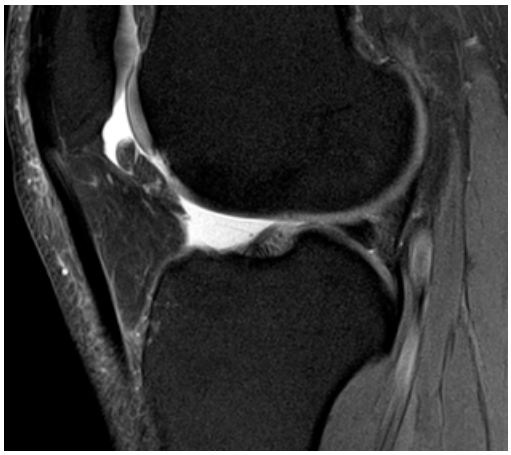

PD Co FS

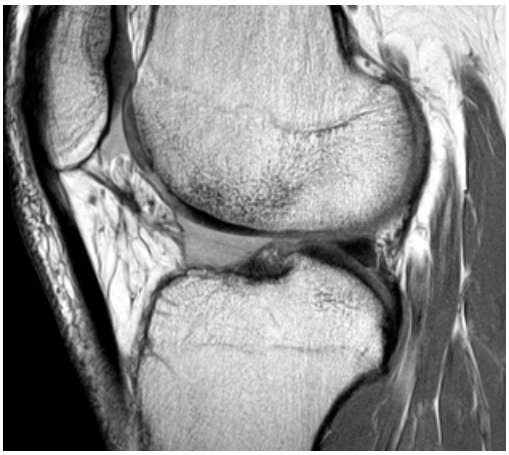

PD sg FS

PD Sg

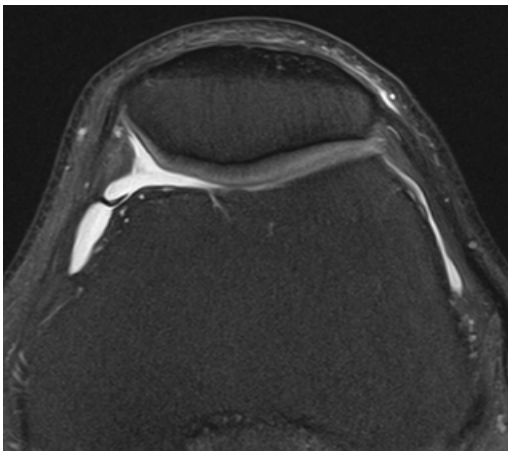

PD Ax FS

The results in this document are the findings of the author. Clinical outcomes may vary dependent upon clinical use and environment.

Case 3: MRI of Left Knee

Patient History:
55 y/o, Left knee pain. Lateral collateral ligament injury.

Technique and Parameters:
On a 3T platform axial, coronal and sagittal PD FS with sagittal PD acquisitions were obtained through the left knee.

	PD Co FS	PD Ax FS	PD Sg Fs	PD Sg
TR [ms]	3500	3157	2958	3130
TE [ms]	28.5	27	27	28.5
Matrix	352	400	336	432
Spatial Resolution [mm]	0.4 x 0.4	0.4 x 0.4	0.4 x 0.4	0.4 x 0.3
Slice Thickness [mm]	3.0	3.2	3.2	3.2
Scan Time [min]	2:41	2:32	2:57	2:49

FINDINGS

There is slight thickening of the medial collateral ligament. The articular cartilage and the wide bone compartment to the knee joint shows partial thickness chondral fissuring on the medial femoral condyle. There is focal full thickness chondral loss overlying the patella and there is minor subchondral bone marrow oedema. There is minor insertional enthesopathy of the quadriceps tendon. There is a moderate knee joint effusion. There is focal grade 4 chondromalacia patella and high grade partial thickness chondral fissure on the medial femoral condyle. A small knee joint effusion is noted.

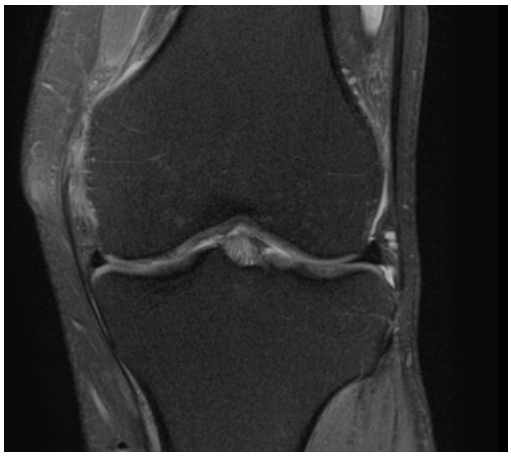

PD Co FS

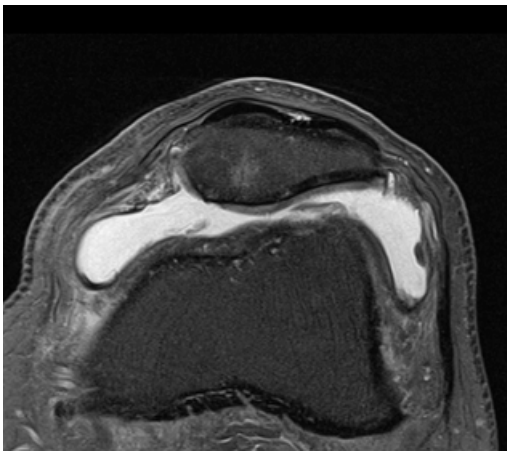

PD Ax FS

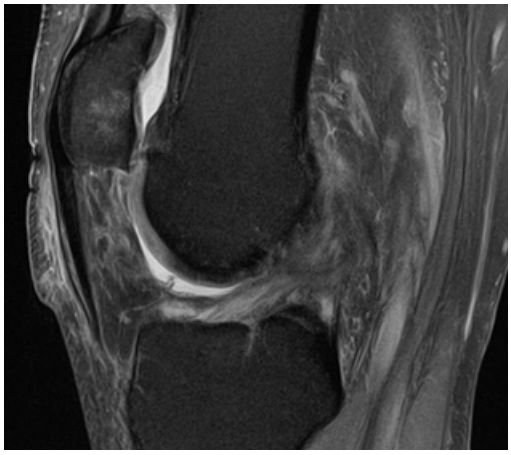

PD Sg Fs

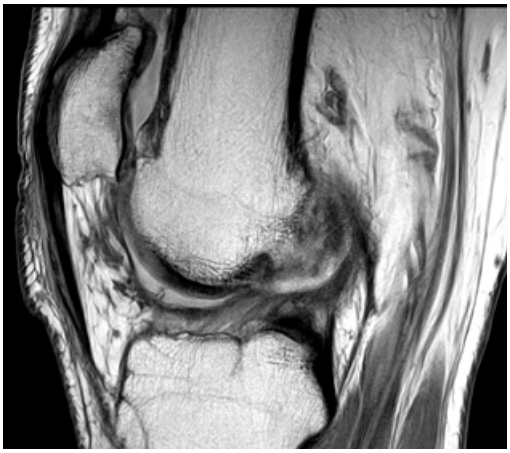

PD Sg

The results in this document are the findings of the author. Clinical outcomes may vary dependent upon clinical use and environment.

Leiden University Medical Center welcomes world's first Aquilion ONE GENESIS Edition

Bringing New Applications into Daily Practice

Leiden University Medical Center (LUMC) in Leiden, the Netherlands was the second hospital in Europe to acquire an Aquilion ONE™ CT system when it was introduced in 2007. Ten years later, it is the very first in the world to welcome Toshiba Medical's latest addition to the Aquilion Family - the new Aquilion ONE GENESIS Edition. Dr. Koos Geleijns, Head of Medical Physics, Dr. Lucia Kroft, Radiologist and Head of the Cardiothoracic Section and Joost Roelofs, Senior Radiographer and CT Expert from LUMC's Radiology Department, explain how the new system enables them to integrate relatively new CT applications seamlessly into everyday clinical practice.

Joost Roelofs, Senior Radiographer and CT Expert , Dr. Lucia Kroft, Radiologist and Head of the Cardiothoracic Section and Dr. Koos Geleijns, Head of Medical Physics from LUMC's Radiology Department.

LUMC acquired the Aquilion ONE GENESIS Edition to provide extra capacity for high-end applications, such as dynamic brain and cardiac perfusion, and to meet growing demand for CT examinations. The number of CT scans requested at the Hospital continues to increase by approximately 5%-7% year-on-year. Following their positive experience with Toshiba Medical's Aquilion ONE and with the launch of the GENESIS in November 2016, the LUMC Radiology Team took the opportunity to acquire a third scanner to complement their existing system.

"So many of our patients require high-end applications these days. We did not have enough capacity with the old scanner and needed another, particularly for cardiac- and neurological scanning, pediatric-, intensive care- and trauma patients," said Dr. Kroft. "The GENESIS is faster than the previous one, which helps with better image quality."

"We already had a lot of cases that could only be done on the Aquilion ONE. With the addition of the new GENESIS, we can now divide the total number of patients over two

Dr. Koos Geleijns, Head of Medical Physics

systems, which helps our workflow enormously," added Joost Roelofs. "Previously, an emergency case in the first aid department could delay another already scheduled in the program, because the emergency has priority."

ADVANCED APPLICATIONS

While CT applications, such as brain perfusion, cardiac perfusion and cardiac CT are generally used in a research context in most hospitals, they are already everyday routine clinical practice at LUMC.
"We were already used to top quality imaging with our Aquilion ONE CT system. The GENESIS builds upon the existing capabilities of the Aquilion ONE and offers us enhanced capacity in many high-end applications," said Dr. Kroft.

IMPROVED IMAGING

With a faster rotation, the GENESIS delivers enhanced performance, image quality and reconstruction times.

"We have some gains for cardiac CT in particular with the faster rotation of the GENESIS. And that's important," said Dr. Kroft. "We have also been able to develop 'free-breathing' protocols for pulmonary embolism, because the new scanner is so fast. So, we can achieve good scans for patients who can't hold their breath."

"Sometimes, patients with pulmonary embolism breathe very fast and cannot hold their breath. The higher rotation speed of the GENESIS enables us to minimize motion artefacts. It's very useful for these cases," added Joost Roelofs.

"The area finder on the new system is very useful."

"The Aquilion ONE GENESIS has the technological capabilities for very low dose CTs "

"Another application that can only be performed on the GENESIS is in CTA examinations, because it offers volume scanning in combination with helical SEMAR (Single Energy Metal Artefact Reduction). With this, we can even scan patients with stents that contain metal elements . This would otherwise cause metal artefacts on another scanner," he continued.

WIDE BORE

With a 78cm wide bore, the GENESIS offers optimal flexibility, ease of use and patient comfort.

"The larger bore of the GENESIS is very useful, particularly for intensive care patients," remarked Dr. Kroft.

"Many of our patients are referred for scans from the Oncology Department and are often older, so their arms are not so flexible. They often have difficulty in positioning their arms upwards. The larger bore makes it a little easier for these patients and helps to position the patient better," added Joost Roelofs.

Joost Roelofs, Senior Radiographer and CT Expert

"We're very happy with the new scanner. Now we have two Aquilions... And one is even better!"

Dr. Lucia Kroft, Radiologist and Head of the Cardiothoracic Section

REDUCED DOSE

A key focus in development of the GENESIS has been on further dose reduction.

"All our pediatric examinations are now done with the GENESIS, because the radiation dose is lower and it is faster," said Joost.

NEW OPPORTUNITIES WITH ULTRA LOW DOSE

The LUMC now explores the opportunities of Ultra Low Dose CT of the chest, with all the advantages of a CT image at the same dose, at the same speed, and at the same ease for the patients as two conventional radiographs of the chest.

"Ultra low dose with AIDR 3D reconstruction really is new," said Dr. Kroft. "What's unique about the GENESIS is that it offers the opportunity for very low dose imaging. We are already benefiting from this in our reserach. In our Ultra Low Dose CT Study, we perform an ultra low dose CT scan in addition to a normal X-Ray in patients referred for routine chest X-Ray examinations. The ultra low dose CT has a comparable radiation dose to the X-Ray. We are exploring the diagnostic outcome of each technique to see if the CT offers any extra value. The CT is a 3D technique, so you can acquire much more information than with the 2D X-Ray technique. This research project has already given very nice results that will be published."

"This is a spectacular study that we are able to carry out because the GENESIS has the technological capabilities for very low dose CT - 3D imaging at the dose of 2D imaging. I think everybody agrees that 3D is the future," remarked Dr. Geleijns.

"In another research project, the low dose capabilities of the GENESIS enable us to scan the whole spine of patients with spondyloartrhitis (SpA)," continued Dr. Kroft. "This means that the research team can look at the spine using a 3D technique instead of a 2D projection, which gives us much more information on the development of syndesmophytes and concomitant pathology. Our researchers are very enthusiastic about this technique."

LASER COLLIMATION

The GENESIS has some groundbreaking new features, including laser collimation. Laser collimation offered by the GENESIS Edition makes it possible to keep dose very low, because preparation to scan the patient is minimal.

"The GENESIS has a special application that allows us to position or plan the scan without the need for a pre-scan. Pre-scan requires so much dose that without this application, we would not be able to achieve Ultra Low Dose 3D imaging at the radiation dose of 2D. The laser makes it possible for the radiographer or technician to plan the scan in a very accurate way," Dr. Geleijns explained.

"In addition, the area finder on the new system is very useful for scans of wrists or elbows. It makes it very easy and fast to scan in a trauma situation or in the Emergency Department. We have a fast way to make a CT scan of the extremities," added Joost Roelofs.

MODEL BASED ITERATIVE RECONSTRUCTION

To achieve further reduction in dose in the GENESIS, Toshiba Medical developed a completely unique, new model-based iterative reconstruction algorithm, called 'FIRST'.

"The GENESIS is the very first scanner to offer Model Based Iterative Reconstruction," Dr. Geleijns pointed out. "We are exploring it at LUMC and will shortly publish the first evaluation of this technology in a paper in the British Journal of Radiology. The initial results show that FIRST gives a better image quality for low dose acquisitions. This is the first step in Model Based Iterative Reconstruction and it is a very good start. We have already seen some positive advantages."

USER-FRIENDLY

The GENESIS was also designed to be even more user-friendly.

Leiden University Medical Center, in Leiden, the Netherlands, is focused on high quality research, education and patient care with a strong scientific orientation.

"The whole line of Toshiba Medical CT scanners is well considered, because, while there are major functional differences between the systems, the installation of successive Toshiba Medical CT scanners is relatively easy, as the footprint of the scanners is more or less the same," remarked Dr. Geleijns.

"The user interface of the GENESIS is more or less the same as the Aquilion ONE. So, it was easy for our technicians to learn how to use the system," said Joost Roelofs, who is responsible for training LUMC's team of Radiology Technicians. "The user interface gives a lot of information in one screen, via pop-up screens or pull-down menus, and as soon as you know where to find all the instructions for the system, it becomes very easy."

PROGRESS

The LUMC Radiology Team recognizes further challenges and that clinical healthcare and imaging industries need to work together to find solutions for - for instance, in cardiac perfusion. It is a challenge to scan patients in a cardiac stress test with lowest dose and optimal results. The Team is generally delighted with the progress and additional opportunities that the GENESIS has brought.

Dr. Koos Geleijns, Head of Medical Physics, Dr. Lucia Kroft, Radiologist and Head of the Cardiothoracic Section and Joost Roelofs, Senior Radiographer and CT Expert and from LUMC's Radiology Department.

Toshiba Medical Receives Green Apple Environment Award 2016

Toshiba Medical has received the prestigious Green Apple Award for its Vantage Elan™ MRI System. The Green Apple Award is a global recognition of innovation that contributes to environmental best practice.

On the right: Mark Holmshaw, Vice President Sales, Marketing & Service at Toshiba Medical Europe.

Specially designed to save space and energy, operate quietly, and provide optimal patient comfort along with top quality imaging capabilities, Toshiba Medical's Vantage Elan™ MRI scanner occupies a minimum footprint in hospitals and reduces power requirements by almost 70%.

"We are honored and delighted to receive this important award and consider it a token of appreciation for our ongoing efforts to reduce overall impact on the environment," said Mark Holmshaw, Toshiba Medical's Vice President Sales, Marketing & Service Europe. "Toshiba Medical's commitment to the environment dates way back to 1975, when plans for an eco-friendly factory in Nasu, Japan were developed featuring a biological water-treatment and purification system. More than 40 years later, our commitment to the environment has intensified. We develop products that offer significant environmental benefits, while providing the best possible medical images to enable medical professionals to make better, faster and more accurate diagnoses for patients, as well as enhanced comfort."

The Vantage Elan MRI scanner features a wide variety of advanced technologies that enable it to deliver outstanding clinical, environmental and economic benefits.

SIGNIFICANTLY REDUCED FOOTPRINT

The new, mobile Vantage Elan MRI scanner has the smallest-in-class installation space (approximately 23 m^2), but offers patients and clinicians almost 50% more inside space than conventional mobile MRI units. However, at just 3.5m wide, it does not require a separate escort vehicle during transportation. In addition, thanks to a unique loading and unloading mechanism, it can be relocated quickly and easily.

The scanner achieves lowest-in-class power consumption of 25 kVA through the combination of a small-capacity power supply, Zero Helium Boil-Off System and ECO Mode technology, which minimizes system operating costs, with power consumption dramatically reduced when the system is idle. Power requirements for the Vantage Elan are approximately one third less than that for other models.

A QUIET MRI FOR EVERY SEQUENCE, SCAN AND PATIENT

Acoustic noise from equipment is a potential nuisance for both patients and medical staff. Toshiba Medical's patented Pianissimo technology, which was first introduced in 1999, dramatically reduces the noise in and around the MRI environment, making examinations more comfortable and easier to complete.

What are The Green Apple Awards?

Green Apple Awards are a prestigious global recognition of environmental best practice issued by The Green Organisation - an international, independent, non-profit, non-political, non-activist environment group that was established in 1994 to recognize, reward and promote environmental best practice around the world.

Vantage Elan

Environmental Profile: Vantage Elan MRI Scanner

Space:
- Compact (approximately 23 m2 installation space).
- Almost 50% more inner space than conventional mobile MRI units.
- 3.5m wide - no need for a separate escort vehicle during transportation.
- Maneuverable and easy to relocate.

Power:
- Low power requirement of 25kVA.
- Reduces power requirements by almost 70%.

CO_2:
- 12.7 ton/year - entire product life-cycle.
- 9.5 ton/year in use.

Noise:
- Reduces MR noise from the source by up to 90%.
- Point: Noise level < Environmental noise + 2dB.

Resources:
- 5.6% reduction in product mass.
- 48% reduction in packaging materials.

The Vantage Elan MRI scanner features a 1.4m ultra-short magnet with excellent magnetic field homogeneity, which ensures ultra high image quality, while ensuring more comfortable examinations and reducing patient anxiety. It is ideal for patients who may be more vulnerable to, or concerned about, the effects of radiation from X-Ray or CT examinations, or those who experience claustrophobia during the examination procedure. The accuracy of the scanner contributes to faster examination times, early detection of abnormalities, and reduction of radiation exposure to technicians and patients.

IMPROVED WORKFLOWS

Toshiba Medical's commitment to producing reliable systems that offer maximum uptime, ensure increased utility and improved workflow for the lifetime of the Vantage Elan MRI scanner.

Modern Liver Imaging Techniques – A New Era in Liver Ultrasound

Dr. Yuko Kono, M.D., Ph.D

Dr. Yuko Kono, M.D., Ph.D Associate Clinical Professor, Departments of Medicine & Radiology, University of California, San Diego, U.S.A.

Hepatocellular Carcinoma (HCC) is the 6th most common cancer worldwide and the 2nd leading cause of cancer death globally[1]. In the United States, HCC is the fastest growing cause of cancer mortality, growing by 2.7% per year from 2003 to 2012. At this rate, there will be an estimated 78,000 new cases in the United States in 2020[2].

Worldwide, the major risk factors for HCC are Hepatitis B (54%) and HCV (31%), which is the #1 cause in the United States[3]. Cirrhosis of any etiology is associated with HCC, and nonalcoholic steatohepatitis (NASH) continues to increase with high prevalence of obesity and metabolic syndromes in the United States[4]. Reducing mortality, by diagnosing HCC while the disease is still amenable to medical or surgical treatment, requires effective surveillance tools.

HCC Screening and Surveillance Recommendation

Ultrasound is a non-invasive imaging modality widely used to evaluate liver disease. The American Association for the Study of Liver Diseases (AASLD) published practice guidelines on the management of HCC and recommended at-risk groups such as patients with cirrhosis of any etiology or specific hepatitis B carriers to be entered into a surveillance program. Ultrasound is the preferred surveillance tool based on a large randomized controlled trial and the recommended surveillance interval is 6 months based on doubling time of HCC[5]. Semiannual US surveillance recommendation is also supported by cost effective analysis. It is the only cost-effective modality for HCC surveillance[6].

Importance of Image quality

One of the main challenges for ultrasound in HCC surveillance is the variability of sensitivity. The pooled sensitivity of ultrasound to detect early HCC with a size smaller than 5cm was reported to be 63%, with a range from 23% to 91%[7]. Ultrasound is operator dependent, equipment and its software can affect image quality, and patient body habitus is also an important factor for the quality. The increased high BMI trend in patients in the United States is a concern. We conducted a retrospective study reviewing 297 ultrasound examinations performed for HCC surveillance, evaluated the image quality and investigated its affecting factors. We found nearly half of the ultrasound examinations (49.3%) of with inadequate quality, and multivariate analysis showed BMI to be the largest affecting factor. A one-unit increase in BMI leads to a 30.8% increase in the odds of having an inadequate image ratings (Kono Y. et al. unpublished data).

Toshiba Aplio™ i-series systems is designed to deliver outstanding clinical performance with enhanced resolution and penetration to improve clinical precision, diagnostic performance and productivity. With the implementation of advanced architecture, iBeam

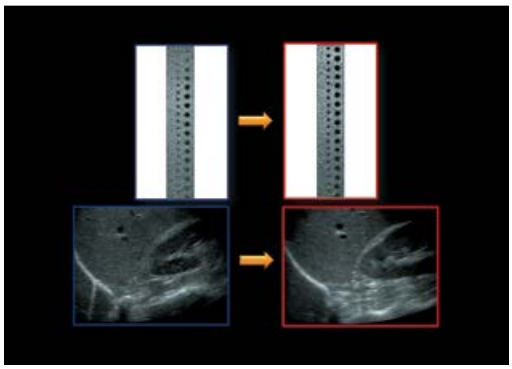

Figure 1: iBeam forming technology generates clinical images with higher resolution, more homogeneity and fewer artifacts.

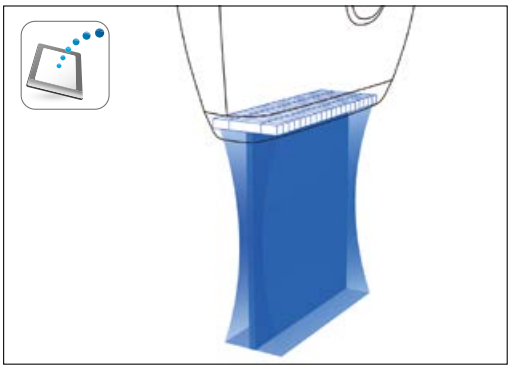

Figure 2: Intelligent Dynamic Micro-Slice (iDMS) technology provides high-flexibility electronic focusing in the lens direction and improves the elevation resolution.

forming technology and Intelligent Dynamic Micro-Slice technology (iDMS) allows the formation of a shaped, uniform and thin slice beam that offers clinical images with higher resolution, more homogeneity, and fewer artifacts. The latest technology offer improvement in contrast resolution, temporal resolution and spatial resolution in all three aspects: axial, lateral and elevation. Aplio™ i-series is equipped with a newly developed iDMS ultra-wideband convex transducer, PVT-475BX. The 2-in-1 ultra-wideband transducer is designed to cover the frequency range normally covered by two transducers, in order to provide both high resolution and penetration.

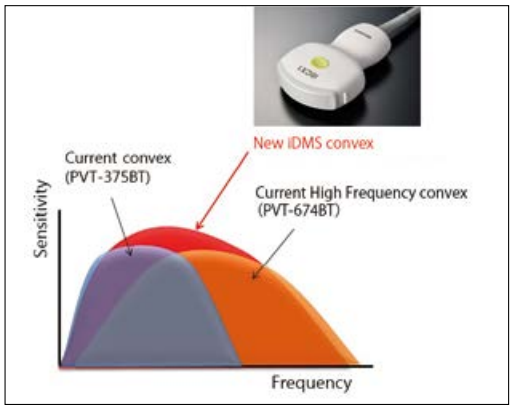

Figure 3. Ultra-wideband iDMS convex transducers

CASE STUDIES

Case 1: Obese patient without known liver disease (BMI 30)

Aplio i-series provides grayscale images with higher resolution, contrast and penetration. With iDMS technology that generates thin-slice beams, homogeneous images throughout the depth can be provided. The increased sensitivity of Doppler images can be demonstrated through Superb Micro-vascular Imaging (SMI). SMI delineates low-velocity minute flows and the detailed vascularity can be visualized.

Figure 4

Case 2: Technically difficult patient with morbid obesity (BMI 40)

The improvement in penetration and image homogeneity ensures high resolution in the technically difficult patient. The back of the liver and texture of the liver parenchymal can be clearly visualized.

Figure 5

CATEGORIZATION OF FOCAL LIVER LESIONS USING CONTRAST ENHANCED ULTRASOUND (CEUS)

Contrast Enhanced Ultrasound (CEUS) is capable to provide real time, high-resolution perfusion information and is one of the state-of-art technologies for differentiation of focal liver lesions. The contrast agents are microbubbles of a few µm in diameter and stable enough to circulate in the body with intravenous injection. Modern ultrasound technology with contrast specific imaging is very sensitive to detect circulating microbubbles, and can visualize dynamic contrast enhancement in a real time manner. In Aplio i-series, spatial resolution, penetration and tissue suppression have been improved for easy observation and accurate diagnosis for categorization of focal liver lesions. Contrast medium Lumason® (Bracco, Italy), (A.K.A. SonoVue® in Europe and elsewhere) was recently approved for characterization of focal liver lesions in adult and pediatric patients in the United States.

CEUS LI-RADS®

The American College of Radiology (ACR) endorsed LI-RADS® (Liver Imaging Reporting and Data System) for standardized reporting and data collection of computed tomography (CT) and magnetic resonance (MR) imaging for HCC in 2011. With the recent approval in the United States of microbubble-based agents for US liver imaging, LI-RADS® has been expanded to include CEUS in August 2016. The LI-RADS imaging criteria are used to classify 'liver observations on high-risk patients' from 'definitely benign' (LR-1) to 'definitely HCC' (LR-5) based on imaging criteria[8]. We expect a categorization algorithm with well-defined CEUS criteria would reduce imaging interpretation variability and errors, and improve communication with referring clinicians and facilitate quality assurance and research. Please note LI-RADS only applies to high-risk patients for HCC.

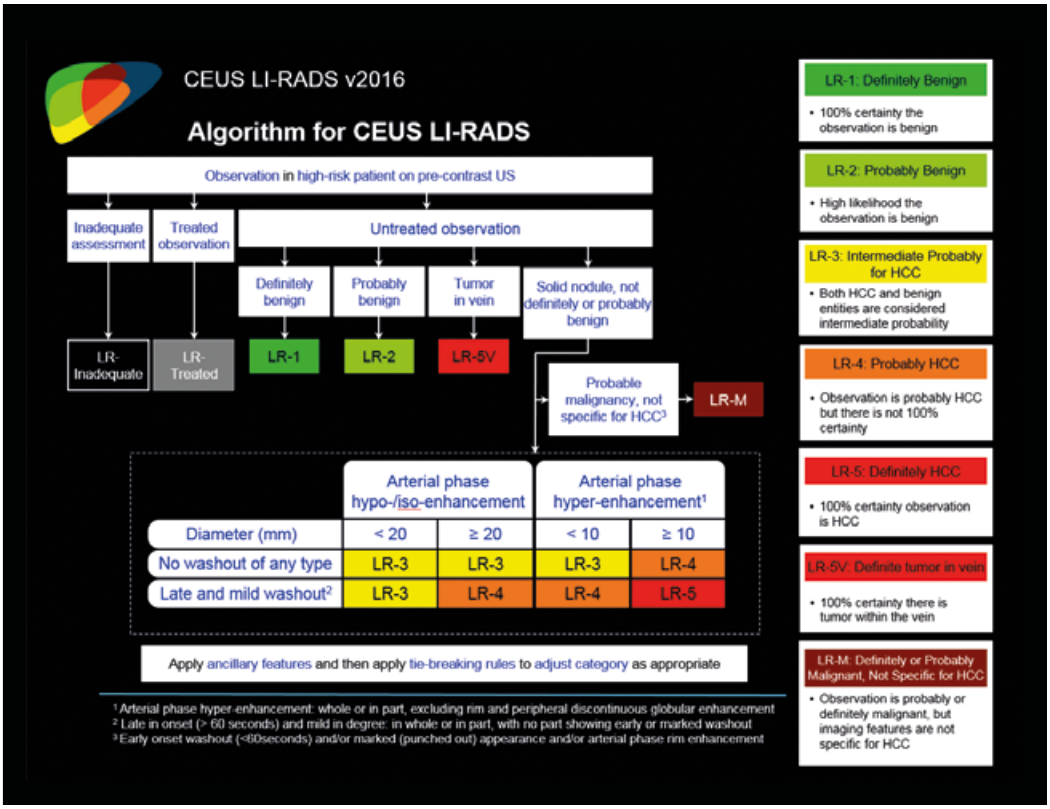

Figure 6. Algorithm and categorization of CEUS LI-RADS®

CASE STUDIES

CEUS is a very powerful tool to observe perfusion pattern of focal liver lesions in real time during arterial phase, portal venous phase and delayed phase, which enables characterization.

Hemangioma

Hemangioma is one of the most common benign liver lesions. The grayscale image from a 50 year-old male shows a heterogeneous hypoechoic lesion in the left hepatic lobe, measuring 3.6 cm in diameter. In the grayscale image, the border and the internal structure of the lesion is clearly depicted. Utilizing SMI, low-velocity minute vessels inside the lesion can be visualized at high frame rates (47fps) and the lesion demonstrated high vascularity. Focal liver lesions can be clearly seen on non-contrast ultrasound with good image quality. Vascularity can be evaluated to some extent. However, diagnosis cannot be made without the use of contrast agent. This is no exception for CT or MRI, both require multiphasic imaging with contrast injection for diagnosis.

The lesion showed a typical enhancement pattern for a hemangioma with an initial peripheral nodular enhancement and centripetal enhancement pattern in the arterial phase. The perfusion of the lesion can be seen clearly based on improvements in tissue suppression with Aplio i-series. The hemangioma continues to show complete hyper-enhancement in the portal venous phase, and become iso-enhancement in the delayed phase. This is a typical pattern of a benign lesion without any type of washout in the portal venous phase or delayed phase.

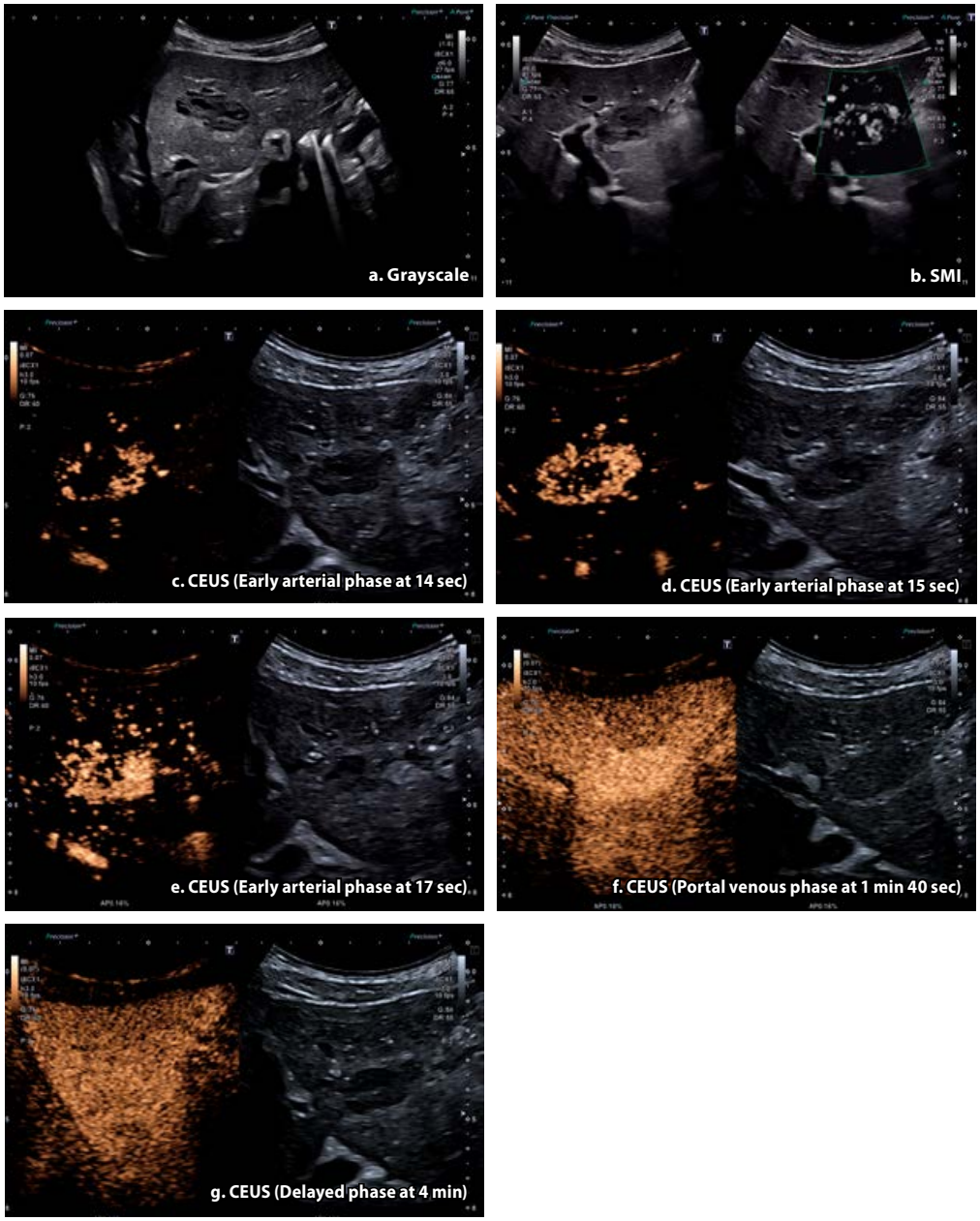

Figure 7

Hepatic Adenoma

This case is a 25 year-old female with multiple hepatic adenomas. The largest lesion is 3.5 cm in diameter, located in segment 6. Although the lesion locates deep at 10cm and is nearly isoechoic to the parenchymal, the image quality in grayscale allows clear observation of the lesion. At a depth of 10 cm, the arterial phase hyper-enhancement, and its vascular pattern can be easily visualized with a peripheral, diffuse pattern towards the lesion center. It is an important diagnostic point to distinguish a hepatic adenoma from a benign focal nodular hyperplasia (FNH) as FNH has similar imaging appearances but enhances from inside to outside. Iso-enhancement in the portal venous phase and delayed phase demonstrate the lesion is benign. Lesions with iso-enhancement can be difficult to track during the late portal venous or delayed phases, however, the clear visualization of the lesion in the grayscale image helps confident tracking of the lesions.

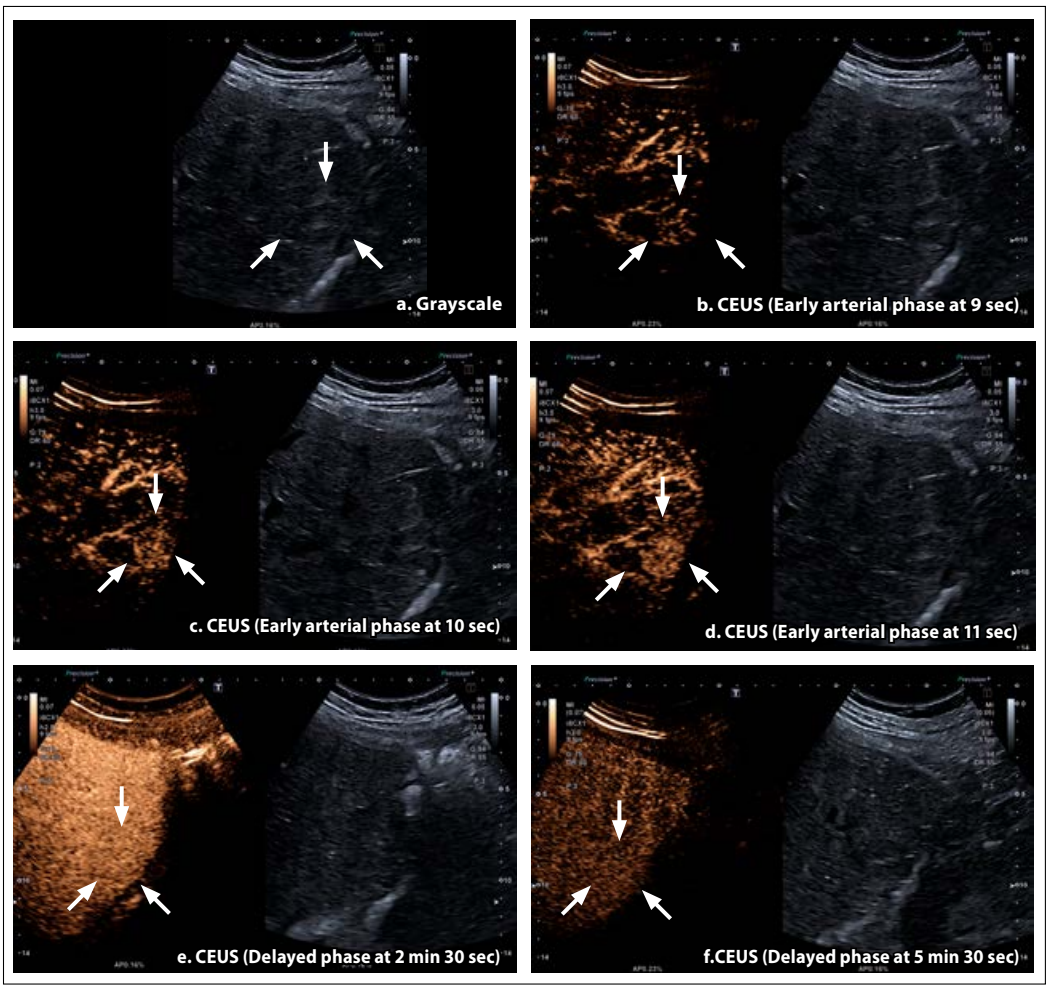

Figure 8

LI-RADS 5 HCC

A 63 year-old female with alcoholic cirrhosis presented with a 3 cm liver lesion. The boundary of the isoechoic lesion and its hypoechoic halo can be clearly depicted on a grayscale image. Using color Doppler, intra-tumoral vascularity can be detected. Rich vascular structure can be delineated with SMI and distorted vessels can be shown, suggesting malignant lesion. After contrast injection, in the arterial phase, the lesion shows homogeneous hyper-enhancement, associated with the feeding vessels. No washout is seen at 1 minute and at 2 minutes. In the delayed phase at 3.5 minutes, mild washout can be observed. Washout slowly progresses and more clear at 5 minutes. Late (≥ 60 sec) and mild washout is one of the major features for LI-RADS 5, and is very important to differentiate from LI-RADS M which shows early (<60 sec) and/or marked washout. As a result, the lesion is categorized as CEUS LI-RADS 5. The CEUS LI-RADS categorization corresponds to the LI-RADS on CT.

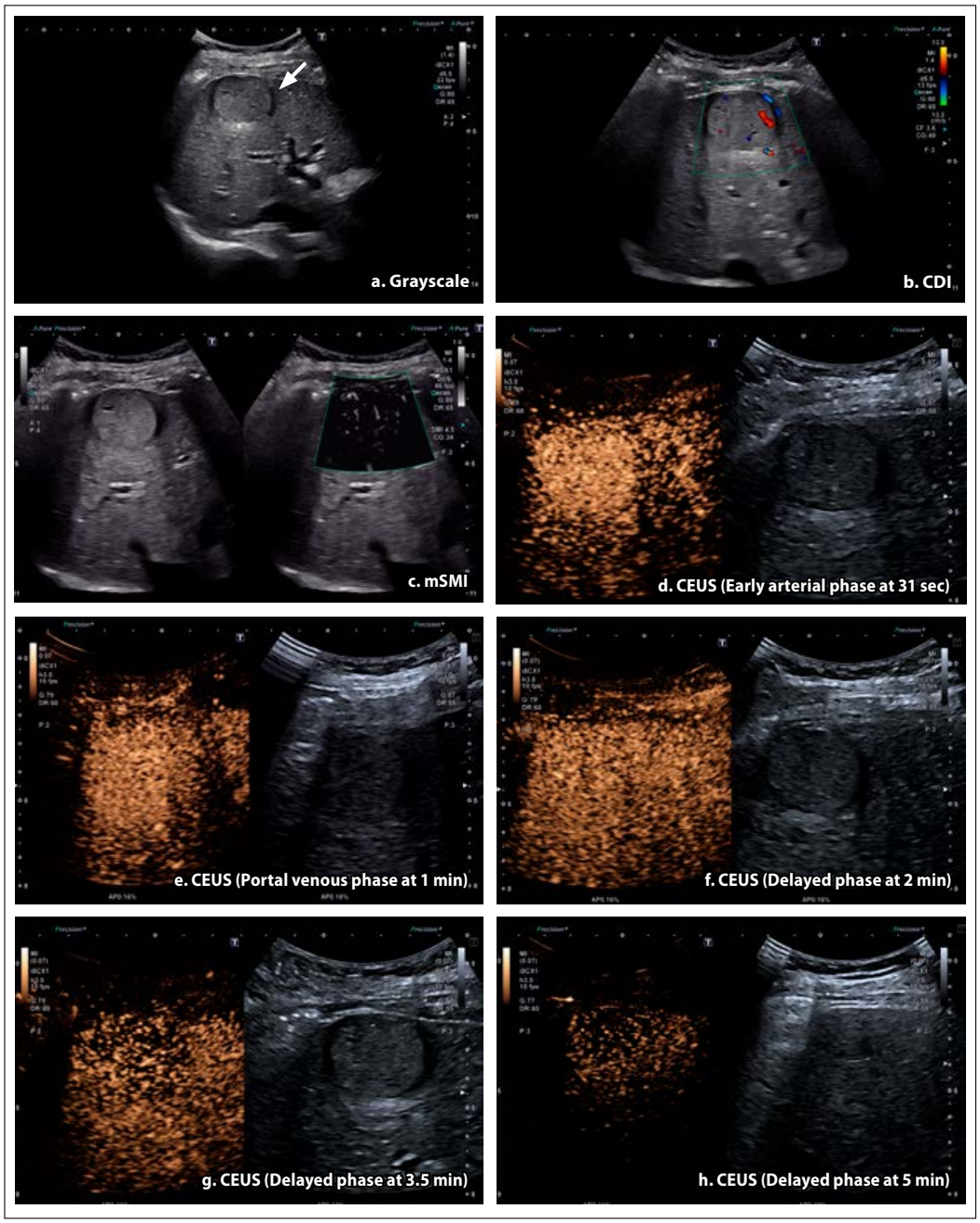

Figure 9

HCC post treatment assessment

A follow-up exam was performed on a 79 year-old male with hepatic B cirrhosis complicated with HCC after trans-arterial chemoembolization (TACE) therapy. A new lesion was detected adjacent to the post-TACE lesion. On the grayscale image, the new lesion is clearly seen, but it is difficult to detect the HCC recurrence in the post-TACE lesion. Using the color-coded SMI (cSMI), rich vascularity can be seen inside the new lesion. CEUS was performed to evaluate the treatment outcome. By using CEUS, both new lesion and HCC recurrent in the post-TACE lesion can be investigated easily. The new lesion shows arterial phase hyperenhancement and no washout up to 5 minutes, therefore, it is a LI-RADS 4 lesion, probable HCC by LI-RADS criteria. Feeding vessels can be observed clearly in the early arterial phase. For the post-TACE treated lesion, majority of the lesion does not enhance, however, hyper-enhancing area were observed in the arterial phase at the upper side of the treated lesion, indicating the HCC recurrence.

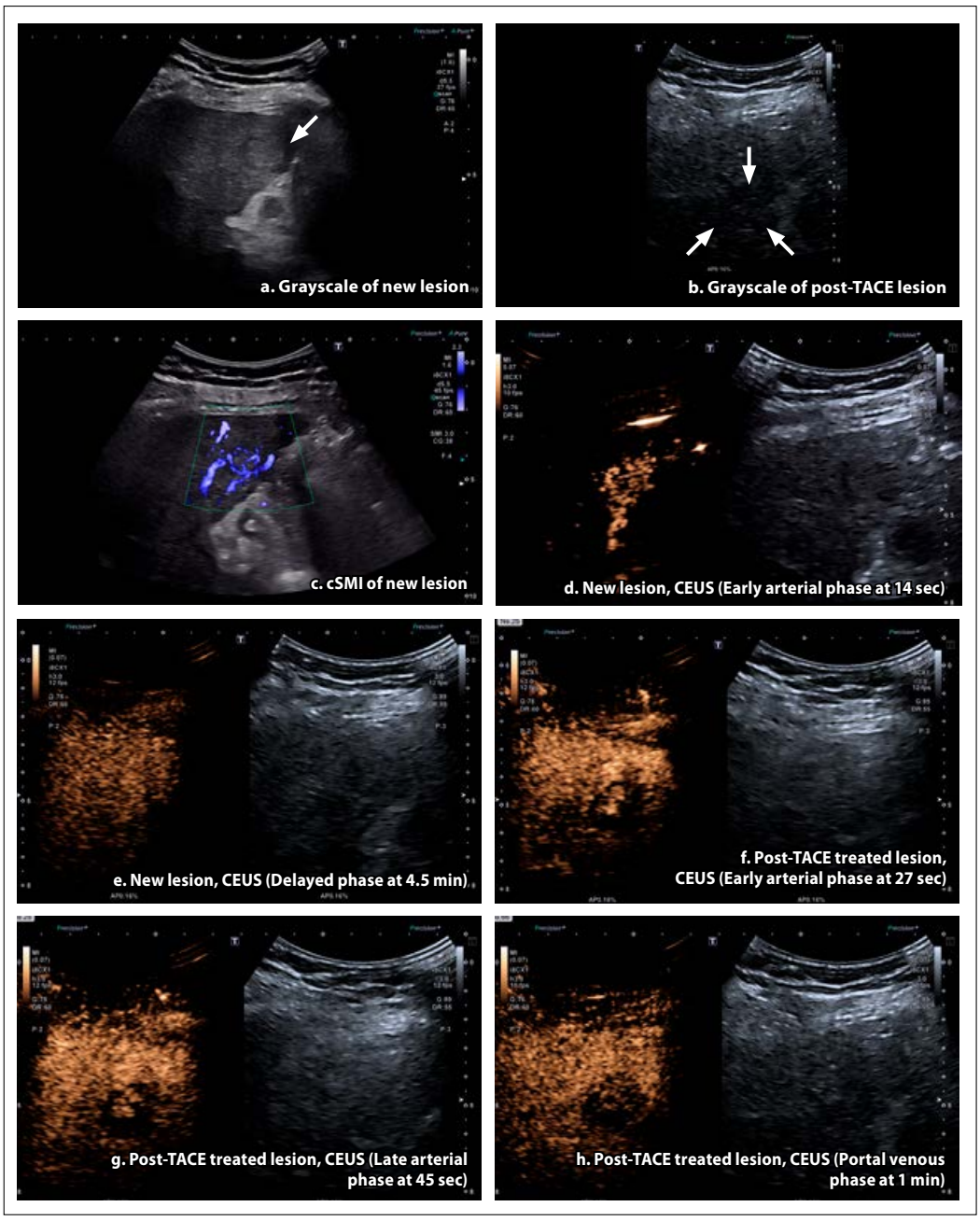

Figure 10

LI-RADS 4 multiple HCCs

This is a case of a 60 year-old female with decompensated HCV cirrhosis with ascites. In the grayscale image, two lesions, 21 mm and 10 mm respectively, located in segment 5 can be detected. Since Toshiba shear wave is performed by push pulse, shear wave examination can be performed on patients with ascites to determine the fibrosis stage. In the early arterial phase, homogeneous hyper-enhancement can be observed in both lesions. The lesions are isoechoic in the portal venous and late phases, no washout was observed at 6 minutes post injection, therefore these lesions were categorized as LI-RADS 4, probable HCC. It is important to know LI-RADS 5 is an HCC with 100% certainty, and it does not require biopsy. Significant numbers of LI-RADS M (probably or definitely malignant, but not specific to HCC) and LI-RADS 4 (probable HCC) are actually HCC.

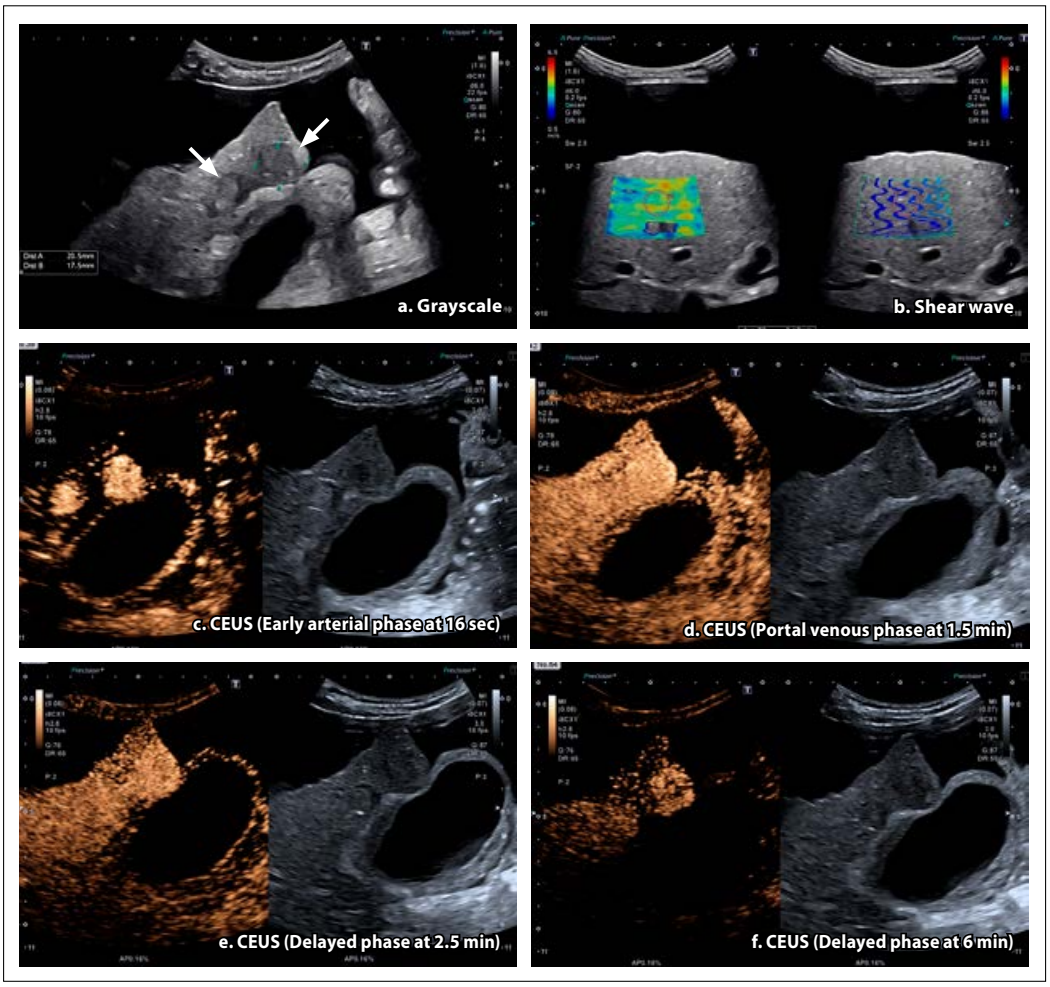

Figure 11

LI-RADS 5 multiple HCCs

A 23 mm lesion was detected in the right hepatic lobe of a 70 year-old female with HCV cirrhosis. Detailed vascular structure and the feeding vessel are clearly depicted with CEUS in the early arterial phase and during portal venous phase, and the lesion is iso-enhancing. This lesion is a typical LI-RADS 5 lesion for its size, hyper-enhancement in the arterial phase and late and mild washout seen at 3 minutes post injection.

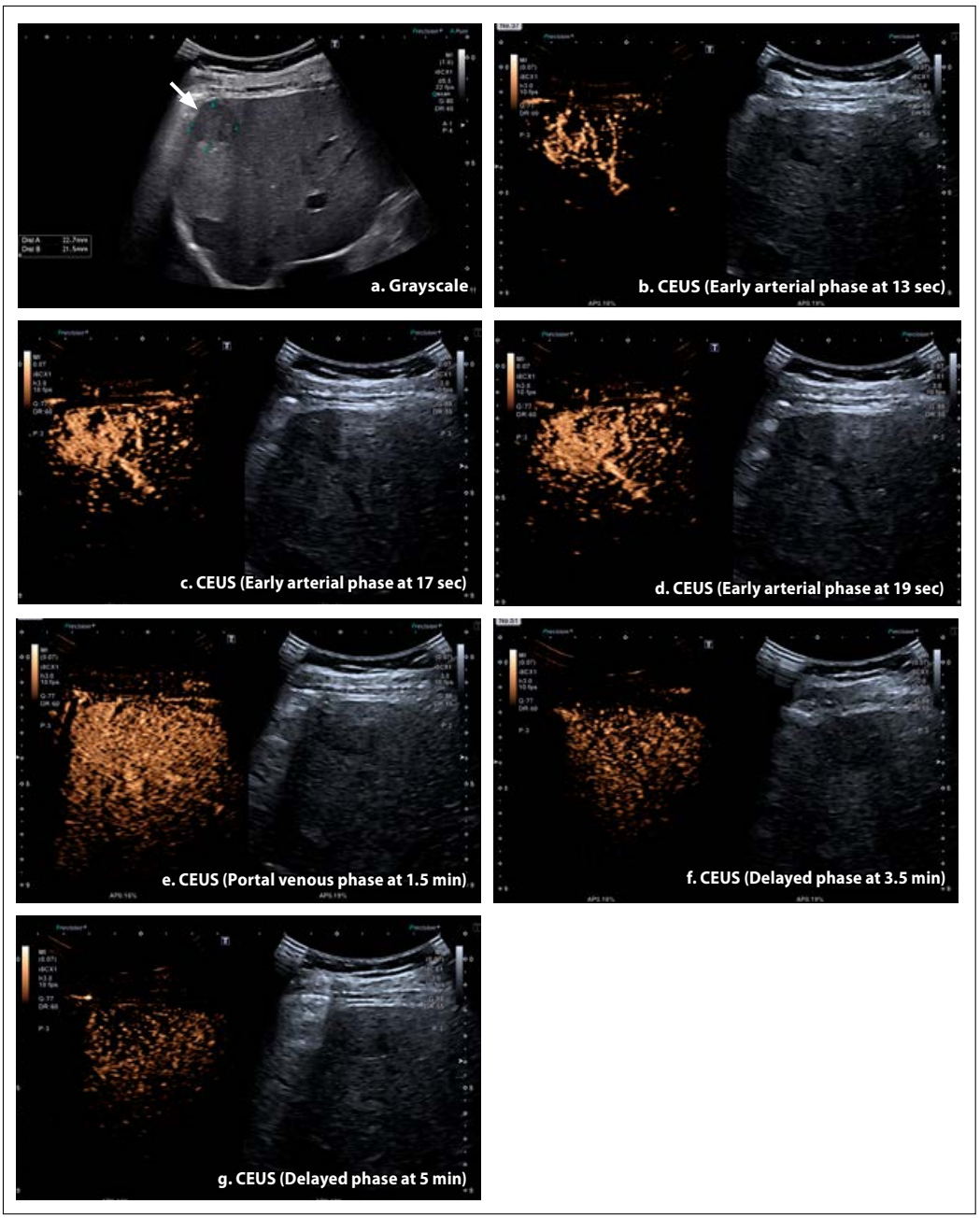

Figure 12

Conclusion

Aplio i-series systems provide unprece-dented imaging clarity and definition while significantly enhancing penetration to overcome difficulties in imaging obese patients and small HCCs. Better image quality even on obese patients is critical to improve HCC surveillance outcome.

The enhanced tissue suppression enables precise and fast diagnosis on differentiating the malignancy of focal liver lesion and CEUS LI-RADS® categorization can be diagnosed accurately. Diagnostic performance and productivity are highly improved based on the high image quality. In addition, the newly designed workflow and system design which offer excellent ergonomic for operators.

CEUS is a cost-effective method for categorization of focal liver lesions without ionizing radiation in adult and pediatric patients. For patients with acute and chronic kidney injury, there is high risk of contrast induced nephropathy by CT contrast agents, and nephrogenic systemic fibrosis by Gadolinium-based MRI contrast agents, and CEUS is a safe alternative as there is no nephrotoxicity. Health care reform is transforming the United States from a volume- to value-based health care system. As that transition continues, CEUS for characterization of focal liver lesions can emerge as an example of a cost-effective and high-value clinical tool.

Reference

1. National Cancer Institute. Surveillance, Epidemiology, and End Results Program. Accessed 11, 2016, from http://seer.cancer.gov/
2. Centers for Disease Control and Prevention. Expected New Cancer Cases and Deaths in 2020. Accessed 11, 2016, from http://www.cdc.gov/cancer/dcpc/research/articles/cancer_2020.htm
3. Llovet JM, Burroughs A, Bruix J. Hepatocellular carcinoma. The Lancet. 2003;362:1907–1917.
4. American Liver Foundation. Non-Alcoholic Fatty Liver Disease. . Accessed 11, 2016, from http://www.liverfoundation.org/abouttheliver/info/nafld/
5. Bruix J, Sherman M. AASLD Practice Guideline: Management of Hepatocellular Carcinoma: An Update. Accessed 11, 2016, from http://www.aasld.org/sites/default/files/guideline_documents/HCCUpdate2010.pdf
6. Andersson, Karin L., et al. "Cost effectiveness of alternative surveillance strategies for hepatocellular carcinoma in patients with cirrhosis." Clinical Gastroenterology and Hepatology 6.12 (2008): 1418-1424.
7. Singal A, Volk ML, Waljee A, et al. Meta-analysis: surveillance with ultrasound for early-stage hepatocellular carcinoma in patients with cirrhosis. Aliment Pharmacol Ther 2009;30:37-47
8. American College of Radiology. Liver Imaging Reporting and Data System (LI-RADS). Accessed 11, 2016, from http://www.acr.org/quality-safety/resources/LIRADS

New Branding for Infinix-i Rite Edition Family

Toshiba Medical has recently introduced new and renamed legacy systems, so customers can easily identify the technology that matches their clinical and patient situation.** With head-to-toe and fingertip-to-fingertip coverage, a 270-degree c-arm pivot, as well as offering the ability to maintain a heads-up display during complex angles with synchronized rotating collimators and flat panel detectors,* the Infinix-i line-up features the following systems:

R Interventional Radiology
C Interventional Cardiology
H Hybrid OR

Infinix-i *Core*
R C

Infinix-i *Core+*
R C

Infinix-i *Sky*
R C

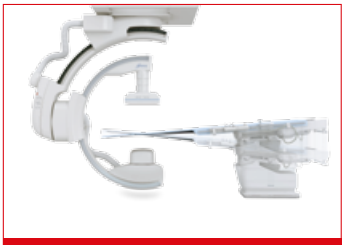

Infinix-i *Sky+*
R

Infinix-i *Hybrid*
H

Infinix-i *Hybrid+*
H

Infinix-i *Dual plane*
H

Infinix-i *Biplane*
R C

Infinix-i *4D CT*

** Not including the Infinix-i Core system.*
*** The Infinix-i Core is the INFX-8000F (SP), the Infinix-i Core + is the INFX-8000V (SP), the Infinix-i Sky is the INFX-8000C with 830 c-arm, the Infinix-i Sky + is the INFX-8000C with 930A c-arm, the Infinix-i Dual-Plane is the INFX-8000F (DP), the Infinix-i Biplane is the INFX-8000V (BP).*

"Toshiba Medical has an XRVL legacy of helping clinicians provide the ultimate in patient access, care and safety," said René Degros, X-Ray Business Unit Manager, Toshiba Medical Systems Europe. "We've been able to continue that legacy with the recent launch of the Infinix-i Sky +, which allows clinicians to move the c-arm around the patient, rather than the other way around."

Infinix-i Sky +

Enjoy the Freedom to See More and Do More

The world's fastest, most flexible angio suite

Providers of interventional imaging systems are being challenged to improve clinical outcome, patient comfort and dose efficiency while reducing cost of ownership and environmental impact. With its unique sliding dual c-arm Infinix-i Sky + provides ultrafast whole body coverage, free head access and a unique lateral c-arm stroke for better ergonomics, improved productivity and stunning 3D images from head to toe.

With 270˚ isocentric rotation, Infinix-i Sky + provides unparalleled flexibility and patient access even for the most challenging procedures. Its dual c-arm design with 210˚ coverage and ultrafast rotation of 80˚/s enables shorter breath hold times, reduced contrast medium and outstanding 3D imaging from head to toe without the need for moving the patient or the table.

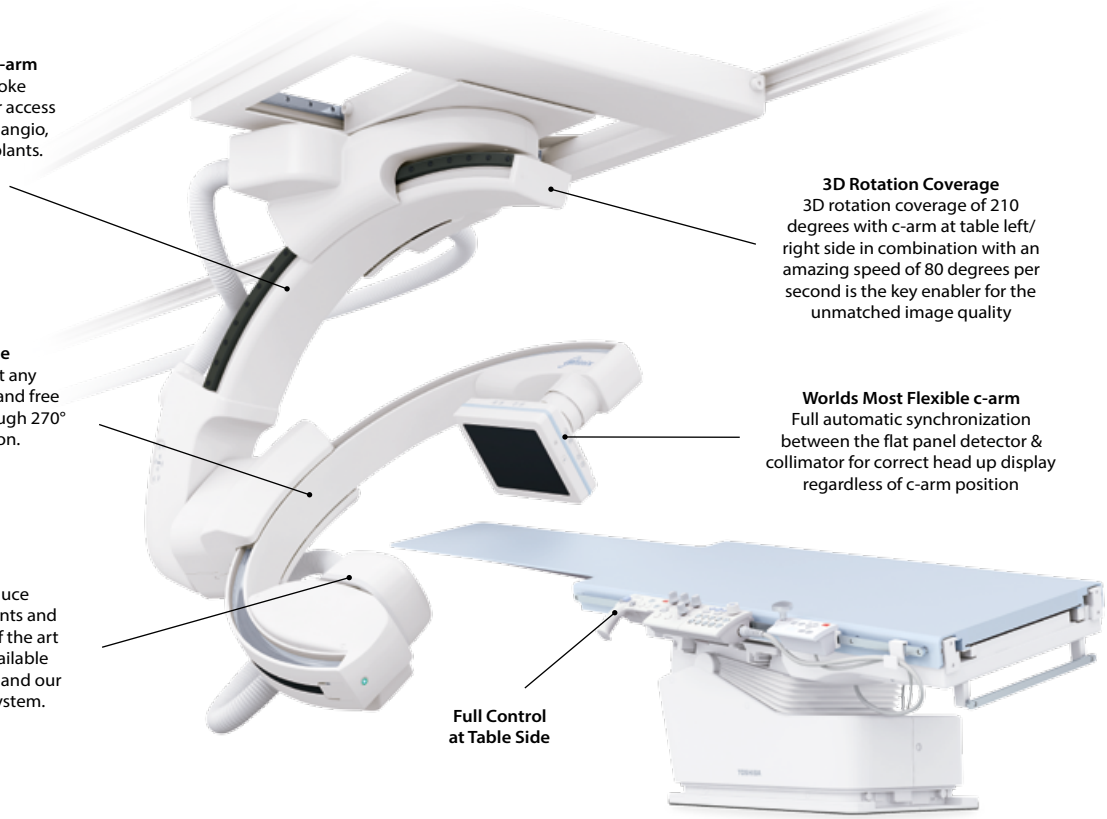

Infinix-i Sky+

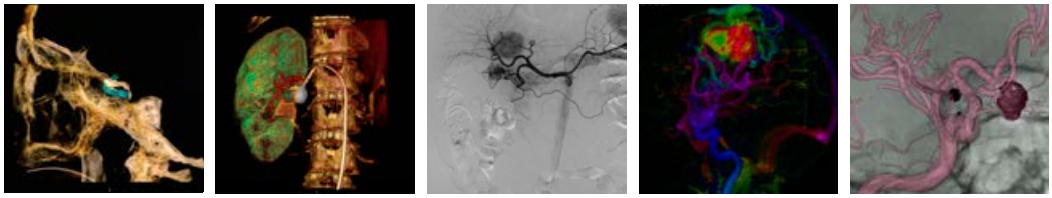

TOSHIBA MEDICAL

Made For life

Xario systems providing more value than ever before in one small package

Superior imaging performance is just one of the key reasons that makes our Xario™ one of the most popular diagnostic ultrasound systems for Women's Health. At Toshiba Medical, we believe that having the best image quality is essential to make a confident diagnosis quickly, in every trimester, time-after-time.

With that in mind, we now introduce the all new Xario Platinum Series with even further enhanced imaging performance and an even more extensive range of OB tools. To celebrate this, we now offer a special OB campaign to our valued customers, to ensure that we provide you with the best tools that help you to overcome the clinical challenges of today, and the future.

Xario

Platinum Series

Precision Imaging **Crystal clear images**

Precision Imaging technology enables you to experience ultrasound imaging as close to reality as never before. From widespread areas to fine details, Precision Imaging reveals greater clinical detail for a fast and precise diagnosis.

Luminance **Advanced 4D imaging (NEW!)**

Luminance is an innovative surface rendering technique that provides a softer, more natural visualization of the human skin. The function's freely movable light source gives you strong visual feedback on depth and detail.

ApliPure+ **Enjoy the perfect picture**

ApliPure™+ combines the advantages of spatial and frequency compounding to provide you with images of unsurpassed uniformity, high contrast resolution and detail, while preserving clinically significant markers.

Organ Effective Modulation: An Effective Method to Decrease Radiation Dose to Radiosensitive Organs

R.M.S. Joemai [1)]

Computed Tomography (CT) is an important diagnostic imaging modality with a growing variety of applications. CT is also a major contributor of patient radiation exposure in diagnostic medical imaging, and the development of technical features to reduce the radiation dose in CT has become an important subject.

R.M.S. Joemai

[1)] Department of Radiology, Leiden University Medical Center

Modern CT scanners are equipped with several technical features to decrease the radiation exposure. One of the most important feature is the tube current modulation (TCM). Toshiba's implementation of TCM is called SUREExposure 3D. This feature enables to modulate using two methodologies: 1 – longitudinal the tube current modulation along the patient axis and 2 – the combination of longitudinal modulation and in-plane modulation between anteroposterior and lateral positions. The tube current of the X-ray tube is constantly being adjusted according to the diameter and attenuation of the investigated object.

Organ Effective tube current Modulation (OEM) is a new method that has recently been introduced to reduce the organ dose for radiosensitive organs. The tube current is reduced over a prescribed 120° radial arc over the anterior position of the body. This feature can be applied to allow a reduction of radiation exposure to superficial organs like the breast and eye lens. In particular, these organs have recently been found to be more radiosensitive than previously assumed. Consequently, the International Commission on Radiological Protection (ICRP) has recommended an increased tissue weighting factor with 240% compared with the previous recommendations.[1]

The purpose of this paper is to describe advantages of OEM in terms of absorbed radiation dose to the radiosensitive organs: eye lens and breast. The organ dose was assessed for a fixed tube current volume acquisition and an OEM enabled volume acquisition on the Aquilion ONE™ CT scanner. Additionally the noise distribution in the axial image reconstruction was assessed.

Materials and methods

ASSESSMENT OF RADIATION DOSE

Phantoms

Radiation dose assessment was performed using the recommended phantoms published by the ICRP.[1] Two digital phantoms representing an average female (height 163 cm, weight 60 kg, body mass index (BMI) 22.6 kg/m^2) and an average male (height 176 cm, weight 73 kg, BMI 23.6 kg/m^2) were used for the dose assessment. The digital phantoms are a realistic representation of a human (Fig. 1).

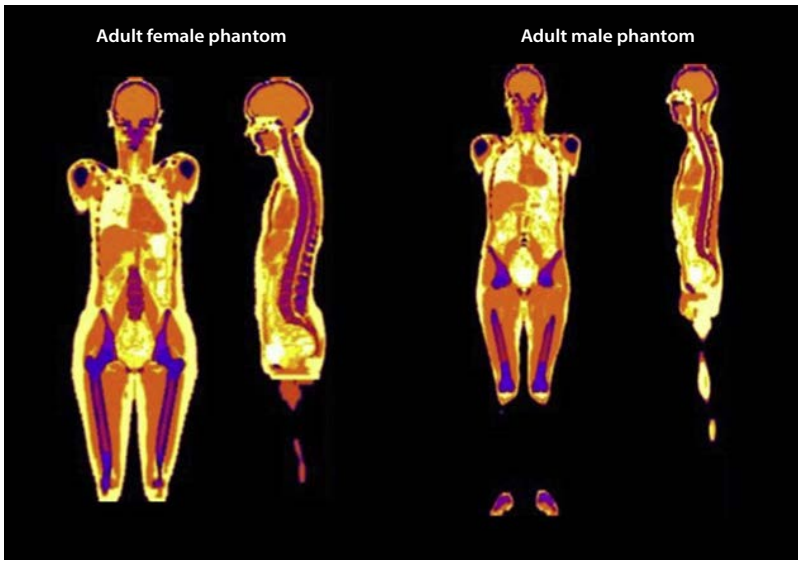

Figure 1: The adult female phantom and the adult male phantom. Coronal and sagittal views show the organs in various colors.

Software for dose assessment

Assessment of radiation dose was performed using a Monte Carlo simulation based program that was specifically designed and validated for dose estimation for a Toshiba Aquilion ONE CT scanner.[2] The program was developed and validated for the Aquilion ONE CT scanner in a previous study, comparing results from MC simulations with the actual measurements acquired under the same conditions in standard CT dose phantoms. The measurements agreed with the dose estimation program across all conditions with relative differences up to 6%.[2]

To achieve accurate dose estimations special implementations were done according to the design of the Aquilion ONE CT scanner. The program contains an accurate model of the actual CT scanner with a special focus on all aspects that have an effect on dose during a CT acquisition, such as X-ray spectrum, X-ray collimation characteristics (including the penumbra), bowtie filtration (related to field size), and heel effect.

The CT acquisition protocol is used as input for the simulation, with parameters such as tube voltage, tube current, pitch, tube position, and scanning range. According to the given parameters, the program calculates the absorbed energy in each voxel of the phantom, and 3D dose distributions are generated.

Analysis of the radiation dose

The program generates three-dimensional (3D) dose distributions for the two digital phantoms. The mean absorbed dose in each organ can be derived from the dose distribution.

Effective doses were calculated using the tissue weighting factors of the ICRP Publication 103[1]. Gender specific calculations of effective dose (E) were performed for the male and female phantoms. The calculations of the effective doses for males were performed without a tissue weighting factor for the breast, and a breast tissue weighting factor of 0.24 was used for the females.

ORGAN EFFECTIVE TUBE CURRENT MODULATION

Organ effective tube current modulation decreases the tube current around the anterior position of the body over 120 degrees. The amount of reduction at the anterior location is determined by the tube current when the tube is at the lateral position of the X-ray tube. The tube current at the anterior position is reduced to 60% compared to the tube current at the lateral position. For an acquisition with a fixed tube current of 300 mA the tube current will be reduced to 180 mA at the anterior position (Fig. 2). Enabling OEM will lead to a lower x-ray tube output compared to the same acquisition protocol without OEM.

MC based dose estimations were performed with the exact function of the tube current. The tube current modulation function was determined using a read out from the generator of the X-ray tube in combination with a read out of the reference detector. The generator gives the level of the tube current that is produced for the x-ray tube and reference detector gives the unattenuated signal of the generated X-rays which is proportional to the tube current. The combination of the two sources of information ensures an accurate determination of the shape and intensity of the tube current modulation. The tube current was determined in relation to the position of the X-ray tube for each 0.3 degree.

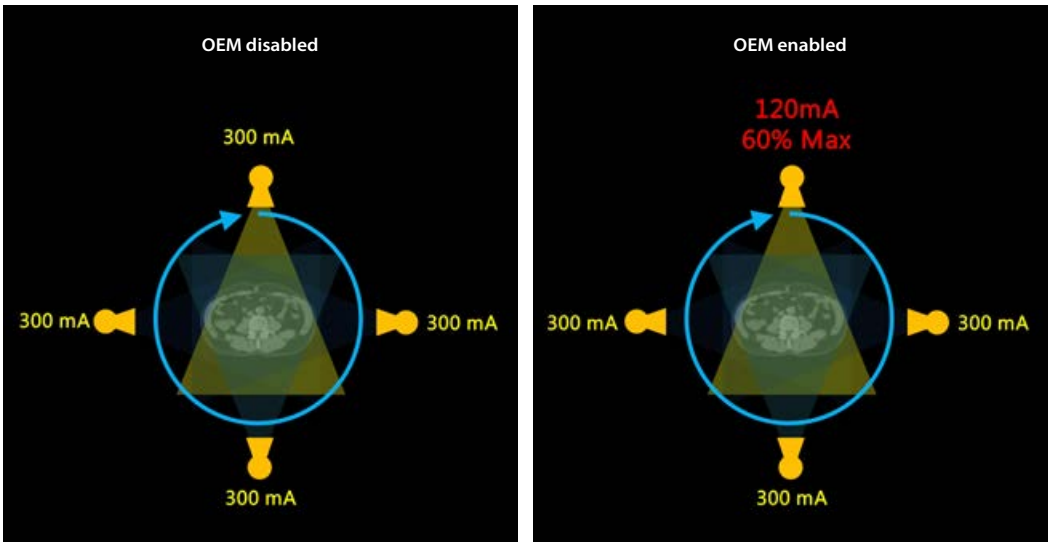

Figure 2: Illustration of the tube current modulation of OEM compared to an acquisition with a fixed tube current. The tube current at the anterior region is reduced to 60% of the tube current at the lateral position.

CT ACQUISITIONS AND RECONSTRUCTION PROTOCOL

Acquisition were performed to retrieve the tube current modulation function and to assess the image quality. Axial acquisitions were performed on a Toshiba Aquilion ONE CT scanner using two phantoms: a standard circular water phantom with diameters of 180 and 320 mm. Each phantom was acquired with and without organ effective modulation using the following parameters: tube voltage 120 kV, tube current 300 mA, rotation time 0.5 s, beam collimation 320x0.5 mm. The 180 and 320 mm diameter water phantom was acquired with a small and large scan field of view, respectively. This protocol was also used for the assessment of radiation dose.

Image reconstruction was performed using the iterative reconstruction technique AIDR 3D, with a slice thickness of 0.5 mm and a reconstruction interval of 0.5 mm. For the small diameter phantom a reconstruction kernel for the head was used (FC26) and for the large diameter phantom a reconstruction kernel for the chest was used (FC08).

IMAGE QUALITY

The evaluation of image quality was performed by calculating a noise map based on the central slice of the volume. The noise map was calculated using the neighboring pixels in 3D. A sliding window of 8x8x8 pixels was used in which the standard deviation was calculated. The calculated result visualizes the axial noise distribution in an homogenous water phantom with and without organ effective tube current modulation.

Results

ASSESSMENT OF RADIATION DOSE

The total output of the x-ray tube decreases when OEM is enabled. This is because the decrease in tube current in the anterior position while the tube current at the posterior position is not compensated by an increase in tube current. The area under the curve of the tube current function was calculated with and without OEM. Enabling OEM for acquisitions without in plane modulation will result in a 13% decrease of the x-ray tube output.

The results of the dose assessment are described for acquisitions when OEM was disabled and enabled. Additionally, the dose results of the acquisition without OEM was lowered with 13% to achieve an equal X-ray output compared to the acquisition with OEM. This will be referred to as 'OEM disabled - X-ray output corrected'.

Reduction of absorbed dose for the eye lens

Fig. 3 shows the absorbed dose of the 6 organs that receives the highest radiation dose resulting from an axial CT acquisition of the brain. Dose assessment shows that enabling OEM in standard use leads to a dose reduction of 31% to the eye lens and a dose reduction of 21% when the x-ray output is kept equal compared to acquisition without OEM.

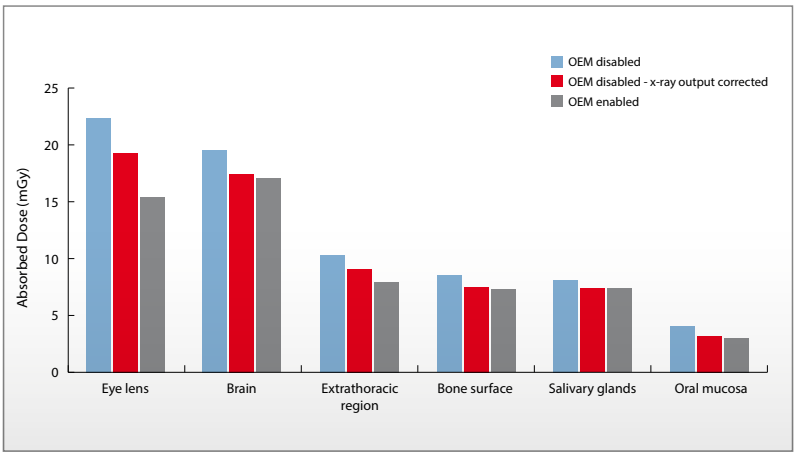

Figure 3: Absorbed dose for six organs receiving the highest radiation dose for an axial CT acquisition of the brain. The absorbed doses are shown for acquisitions when OEM was disabled and enabled. Additionally, the results of OEM disabled was corrected to achieve an equal x-ray output compared to OEM enabled acquisition.

The effective dose of the CT brain acquisition without OEM was 0.69 mSv (0.60 mSv after correction for X-ray output) and for the acquisition with OEM 0.58 mSv.

Fig. 4 shows the obtained dose distributions in the male and female phantom during the CT acquisition of the brain. The axial slice located at the level of the eyes are shown to visualize the reduction on the eye lens when OEM is enabled.

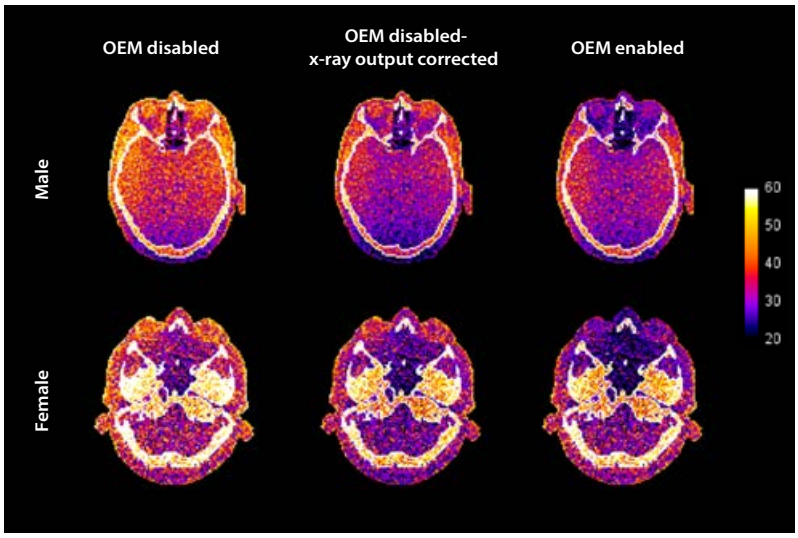

Figure 4: Dose distributions in adult male phantom (top), and adult female phantom (bottom) for an axial CT brain acquisition under three conditions. Pixel value represents the absorbed dose (mGy).

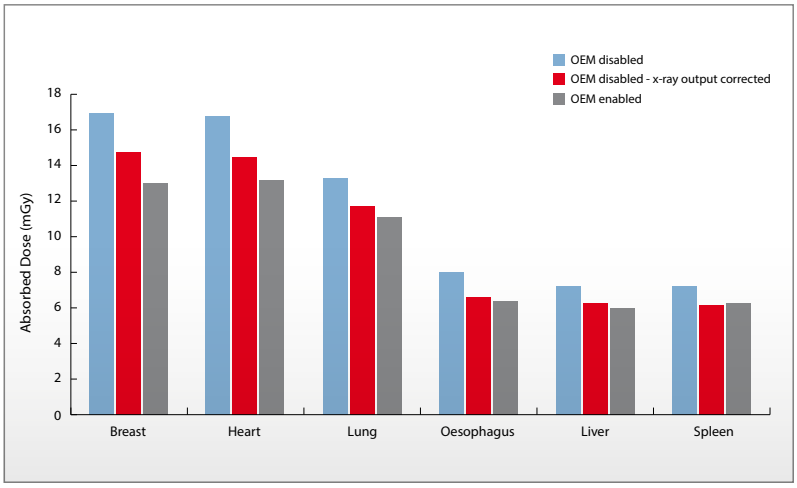

Figure 5: Absorbed dose for six organs receiving the highest radiation dose for an axial CT acquisition of the chest. The absorbed doses are shown for acquisitions when OEM was disabled and enabled. Additionally, the results of OEM disabled was corrected to achieve an equal x-ray output compared to OEM enabled acquisition.

Reduction of absorbed dose for the breasts

Figure 5 shows the absorbed dose of 6 organs that receive the highest radiation dose resulting from a axial CT acquisition of the chest. Dose assessment shows that enabling OEM in standard use lead to a dose reduction of 23% to the breasts and a dose reduction of 12% when the x-ray output is kept equal compared to the acquisition without OEM.

The effective dose of the CT chest acquisition without OEM was 6.1 mSv (5.3 mSv after correction for X-ray output) and for the acquisition with OEM 4.9 mSv.

Fig. 6 shows the obtained dose distributions in the male and female phantom during the CT acquisition of the chest. The axial slice located at the level of the breasts are shown to visualize the reduction on the breasts when OEM is enabled.

ASSESSMENT OF IMAGE QUALITY

Fig. 7 shows calculated relative noise distribution in a 200 mm and 320 mm water phantom resulting from acquisitions with OEM disabled and enabled. No change in the relative noise distribution was noticed when OEM was enabled for the 320 mm water phantom. However, relative noise differences show for the 200 mm water phantom a slight increase in image noise in the anterior region where the tube current is lowered.

DISCUSSION

OEM is a new technique in CT scanning that reduces the tube current over a predefined region of the body and is specifically designed to reduce the dose to radiosensitive organs. This study examined the absorbed radiation dose to the breast and eye lens while OEM was disabled and enabled. The image quality was assessed by an evaluation of the noise distribution in the axial plane.

There are two main strategies for the reduction of dose to radiosensitive organs: bismuth shielding and OEM. Bismuth shielding can potentially reduce the radiation exposure to the female breast by up to 37.5%, but it also leads to a significant increase in artifacts and image noise[3]. The increase in noise and artifacts has such a negative impact on image quality that a more efficient organ dose reduction can be achieved by reducing the dose

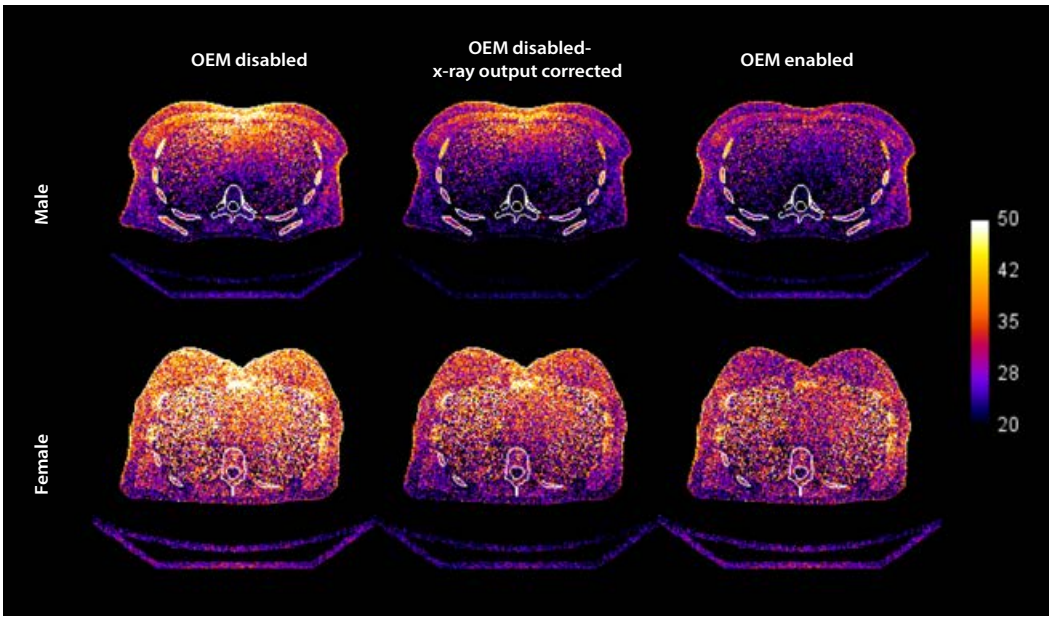

Figure 6: Dose distributions in adult male phantom (top), and adult female phantom (bottom) for an axial CT acquisition under three conditions. Pixel value represents the absorbed dose (mGy).

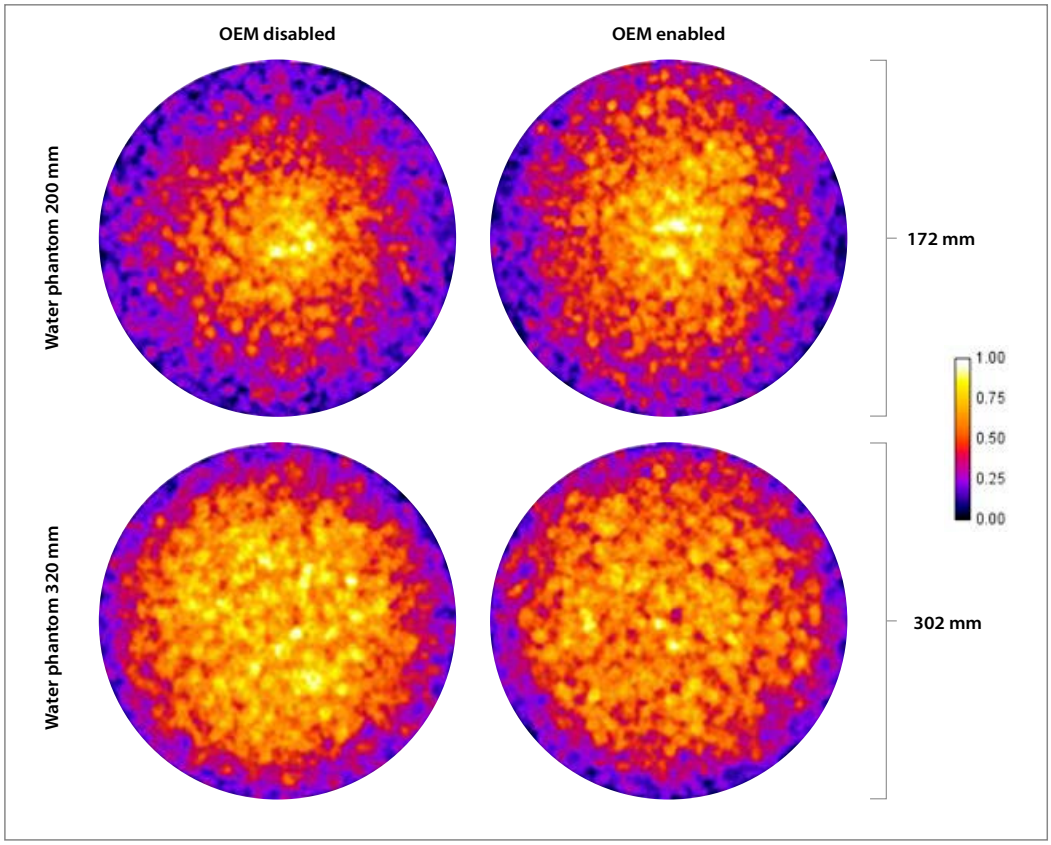

Figure 7: Relative noise distribution calculated for two phantoms with OEM disabled and enabled.

of the acquisition protocol.[4] The application of bismuth shielding is therefore discouraged.

Reducing the radiation dose of the acquisition protocol can be achieved by a manual reduction of the tube current. This way an overall reduction of organ dose is achieved, however the image quality might be downgraded due to the lower radiation dose. A more advanced solution for the reduction of radiosensitive organs is to use OEM. Similar to bismuth shielding, the aim of OEM is the protection of radiosensitive organs near the anterior body surface such as the female breast or eye lens. This is achieved by an angular beam modulation and reduced tube current for the anterior 120°. The major advantage of OEM is the feasibility of reducing the dose to radiosensitive organs without an increase in noise or artifacts.

OEM reduces the radiation to radiosensitive organs such as breast and eye lens while the noise distribution show only slight differences. The use of OEM can be specifically beneficial for a CT of the brain and chest.

ACKNOWLEDGEMENT

Maria Cros (Faculty of Medicine and Health Sciences, Universitat Rovira i Virgili, Tarragona, Spain) is acknowledged for her help with the dose estimations.

References

1. The 2007 Recommendations of the International Commission on Radiological Protection. ICRP publication 103. Ann ICRP. 2007;37(2-4):1-332.
2. Salvadó M, Cros M, Joemai RM, Calzado A, Geleijns J. Monte Carlo simulation of the dose distribution of ICRP adult reference computational phantoms for acquisitions with a 320 detector-row cone-beam CT scanner. Phys Med. 2015 Jul;31(5):452-62. doi: 10.1016/j.ejmp.2015.04.007.
3. Vollmar SV, Kalender WA. Reduction of dose to the female breast as a result of spectral optimisation for high-contrast thoracic CT imaging: a phantom study. Br J Radiol. 2009 Nov;82(983):920-9. doi: 10.1259/bjr/28017710.
4. Geleijns J, Salvadó Artells M, Veldkamp WJ, López Tortosa M, Calzado Cantera A. Quantitative assessment of selective in-plane shielding of tissues in computed tomography through evaluation of absorbed dose and image quality. Eur Radiol. 2006 Oct;16(10):2334-40.

Aplio i-series: Evolution and Revolution of System Architecture with New Generation Technology

Tomohisa Imamura [1], Koichiro Kurita [1], Hiroyuki Shikata [1], Tetsuya Kawagishi [1]

Tomohisa Imamura

Koichiro Kurita

Hiroyuki Shikata

Tetsuya Kawagishi

[1] Toshiba Medical Systems Corporation

Toshiba Aplio™ i-series diagnostic ultrasound systems are the result of intelligent implementation of innovative technologies that provide intuitive experience for its users from the very first moment. The new generation architecture and advanced transducer technology provide an extraordinary experience with fast and easy workflow combined with superb imaging and clinical applications.

Toshiba Aplio i700, i800, and i900 have been designed for whole body ultrasound examinations. The key differentiators of i-series are innovative beam forming technology (iBeam forming), front-end Intelligent Dynamic Micro-Slice technology (iDMS), powerful multiplexing technology and advanced volume matrix technology. The evolution and revolution of architecture with new generation technology provide a new level of image quality and clinical applications.

ARCHITECTURE

More than fifty years of in-house ultrasound evolution has shaped the architectural base of the Aplio i-series. The architecture of Aplio i-series has been designed to prepare clinicians for the challenges of today and the future. In the following section, iBeam forming and multiplexing technology will be explained in more detail.

iBeam Forming

iBeam forming consists of 3 technologies that work together to cumulatively optimize efficiency of the ultrasonic beam: Multi-Sync Pulser (transmitting), Multi-Beam Receiver (receiving), and Multi-Harmonic Compounding (processing).

iBeam ensures the formation of a sharp, uniform and thin slice beam that offers clinical images with higher resolution, more homogeneity, and less artefacts. This revolutionary beam forming technology is able to offer excellent contrast resolution, temporal resolution and spatial resolution in all three aspects: axial, lateral and elevation (or azimuthal).

iBeam Transmission: Multi-Sync Pulser

To obtain high resolution clinical images, harmonic imaging is executed which means that fundamental signals are rejected and second harmonic signals are extracted. Tissue harmonic signals have a narrower beam, lower clutter noise with lower side-lobe levels and thus can form high resolution clinical images. Pure transmitting ultrasound waves are required to reduce artefacts and the clutter that create noisy frequency components in the

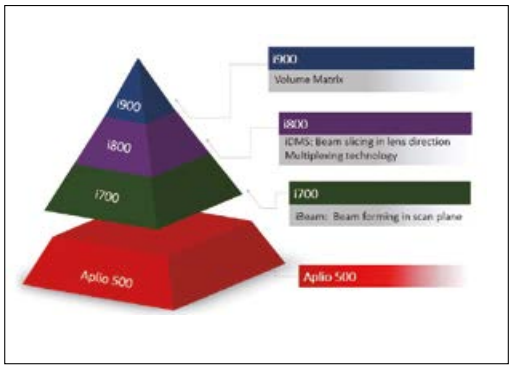

Figure 1: Toshiba's Aplio differentiation chart

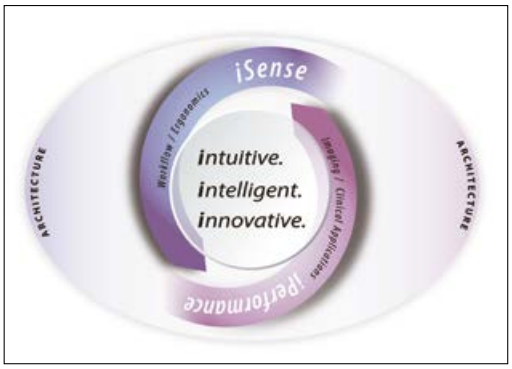

Figure 2: Design concept of Aplio i-series

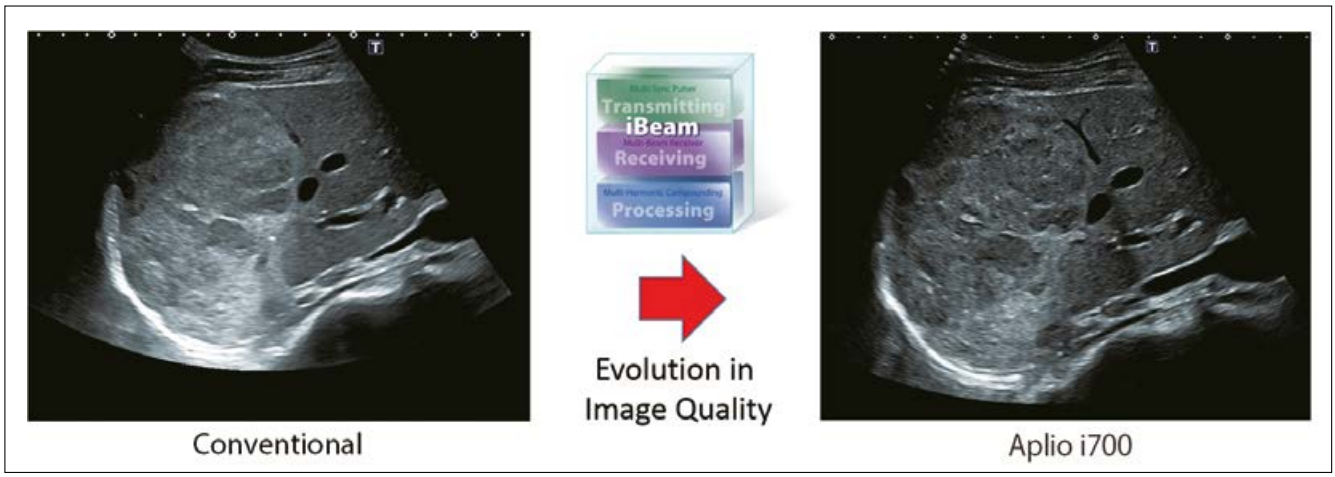

Figure 3. iBeam architecture

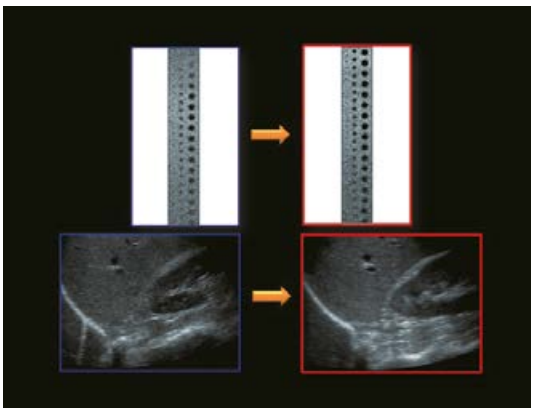

Figure 4. iBeam forming

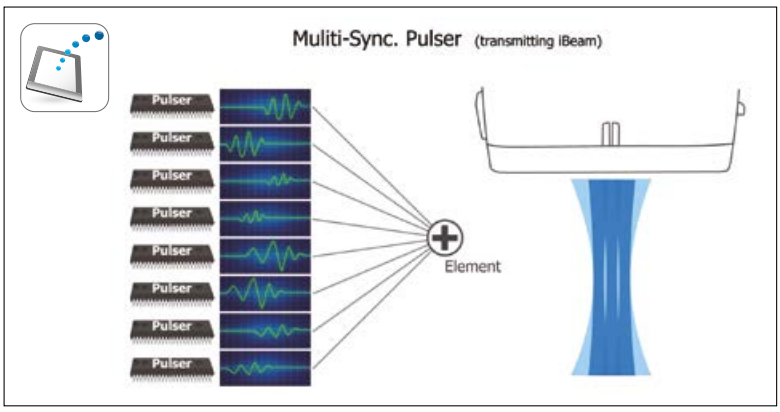

Figure 5. iBeam transmission: Multi-Sync Pulser

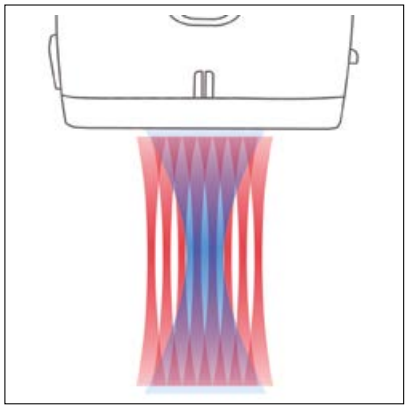

Figure 6: iBeam receiving: Multi-Beam Receiver

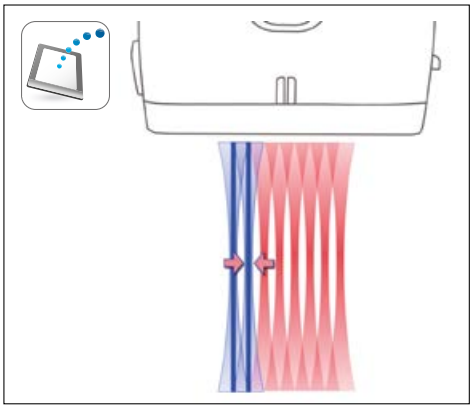

Figure 7 : iBeam processing: Multi-Harmonic Compounding

Figure 8: Intelligent Dynamic Micro-Slice (iDMS) technology

tissue harmonic area. In the conventional Aplio system, a twin-pulser technique was used to transmit purer waves. However, in order to have perfectly pure waves that are artefact-free and homogeneous without decreasing the frame rate, the next generation beam transmitting technology, Multi-Sync Pulser, has been developed. This new beam forming technology can generate symmetrical pulses with a flexible variation in aperture and delay curve for constructing the best artefact-free frequency component. As a result, ultrasound images with more penetration, higher spatial resolution and contrast resolution with reduced artefacts and clutter can be obtained.

iBeam Receiving: Multi-Beam Receiver

Quadrature signal processing (QSP) in conventional systems has an advantage of higher frame rate with one beam transmission because four signals can be received simultaneously. However the newly implemented

Multi-Beam Receiver technology allows multiple beam lines to be received concurrently with one transmission, resulting in a uniform, high density field of scan lines that enable images with more homogeneity and higher frame rate.

iBeam Processing: Multi-Harmonic Compounding

Multi-Harmonic Compounding is a new beam shape forming technology made possible with the powerful processing capacity on the i-series platform. By compounding signals from the main beam and the adjacent beams, a finer, sharper and more uniform ultrasound beam can be generated, leading to precise clinical images with higher lateral resolution and higher frame rate. With Multi-Harmonic Compounding, the signal-to-noise ratio is increased, offering better image resolution and penetration.

PIONEERING TRANSDUCER TECHNOLOGY

Revolutionary i-series architecture leads to next generation transducer technology that can deliver images with more clinical benefits, such as an increased penetration for difficult patients, and a higher resolution that helps to make a diagnosis faster. Aplio i-series transducers can be distinguished from conventional transducers by Intelligent Dynamic Micro-Slice (iDMS) and Volume Matrix technology.

The newly developed low attenuation lens, high performance piezoelectric oscillator and optimized matching layer form the foundation for Intelligent Dynamic Micro-slice technology. iDMS is incorporated in the new 1.5D array transducers in Aplio i800 and i900 series for producing sharp and uniform beams in the lens direction, i.e. providing ultra-thin and uniform slices for enhanced elevation resolution. iDMS is a ground-breaking transducer technology that provides high-flexibility electronic focusing in the lens direction. With iDMS, focusing is not only done by aperture control but also by time delay and weighting control between center and adjacent elements. This technology, generates a continuous focused beam in the lens direction at all depths. The result is a sharp and homogeneous slice thickness with high sensitivity, contrast and elevation resolution.

Ultra-wideband Transducers

Aplio i-series transducers have a significantly wider bandwidth and can cover the frequency range normally requiring two transducers.

The 2-in-1 ultra-wideband transducers contain single crystal and re-engineered materials including a new lens, piezoelectric oscillator, and matching layer. This provides optimum resolution and penetration in one transducer, thereby improving the clinical capability, decreasing examination times, and potentially reduce the financial burden ensuring more effective management of transducers. The innovative ultra-wideband transducers are available for both convex and linear to cover a wide variety of clinical applications.

Professor David Cosgrove, MD.

Imperial College School of Medicine and Consultant in Radiology, Hammersmith Hospital, London, the United Kingdom

"The ultra-wideband transducers i8CX1 and i18LX5 provide excellent images with high spatial resolution and contrast. With iBeam forming and iDMS technology, sharp and uniform images can be acquired easily. In addition, the new ultra-wideband transducer provide increased penetration at the same time.

The image of liver metastases (Figure a) acquired using the i8CX1 shows high resolution, contrast and penetration. The image is really uniform and contains extraordinary detail. The outline of the color Doppler signal has been enhanced (Figure b), allowing detailed observation of the vasculature.

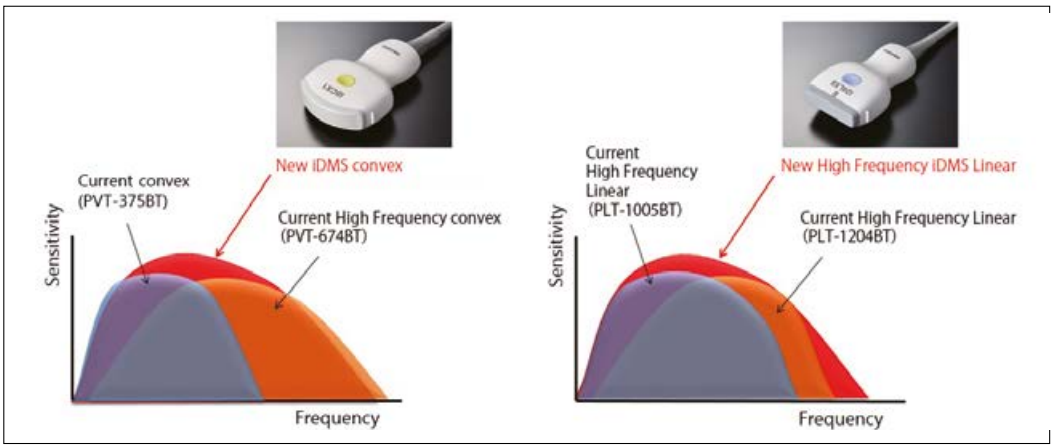

Figure 9: Ultra-wideband transducers

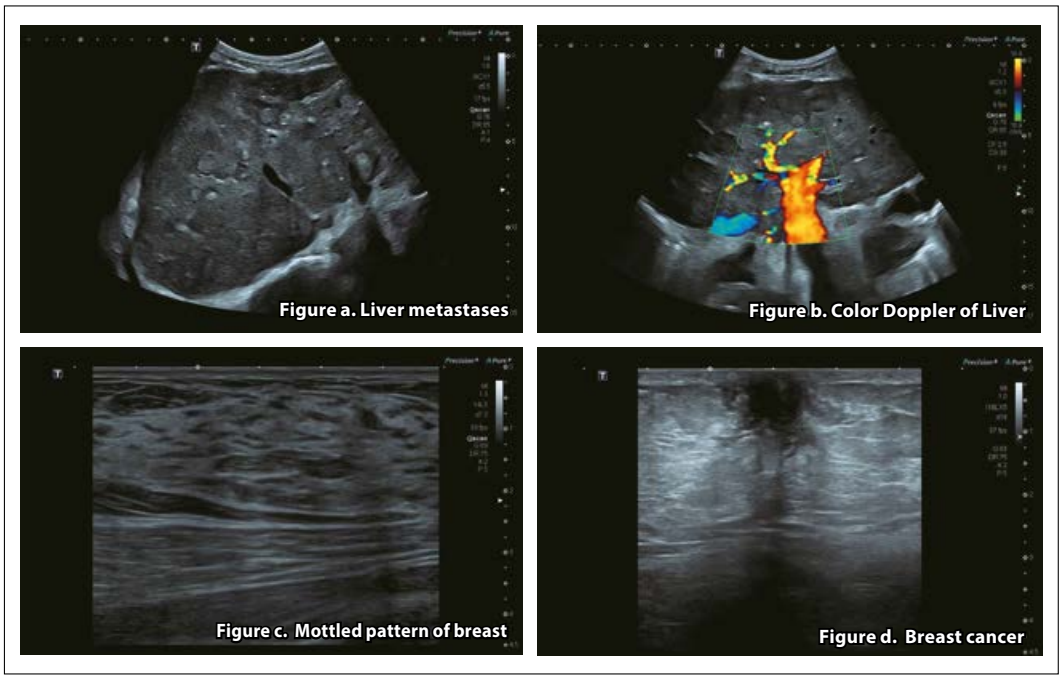

Figure 10: Courtesy of Professor David Cosgrove, MD.

The i18LX5 wideband transducer is an outstanding versatile transducer that bridges many small parts applications. The 2-in-1 transducer provides exceptional detail and high penetration. The mottled pattern in the breast (Figure c) can be observed with great contrast, resolution and uniformity, especially at depth. The invading margin of the breast cancer (Figure d) is clearly shown in detail with good penetration."

** All images were provided by courtesy of Professor Adrian Lim, Imperial College London.*

Ultra-high Frequency Transducers

The new i-series transducer i24LX8 offers an ultra-high frequency (UHF) up to 24MHz with outstanding spatial resolution. The new lens, piezoelectric oscillator, matching layer and backing combination allow high frequency emission. The elevated frequency range expands the horizon for clinical applications especially for small parts, MSK and other potential clinical regions such as dermatology.

Professor Jiro Hata, MD.

Dept. Of Clinical Pathology and Laboratory Medicine, Kawasaki Medical School, Kurashiki, Japan

"For me, the i24LX8 transducer has become irreplaceable for diagnosis. The high frequency transducer has an extraordinary high spatial resolution that is useful for clinical regions such as thyroid, breast, vascular and MSK. At Kawasaki University, we receive a lot of requests for skin ultrasound. With the high resolution, the epidermis and dermis can easily be differentiated and the origin of the lesion can be diagnosed accurately. A malignant melanoma (Figure e, f) which is only 1 mm thick, can be observed in high resolution, followed by SMI to visualize its vasculature.

It is thought that penetration usually is a limitation for high frequency transducers, however, it is possible to examine the liver and gastrointestinal tract (Figure g, h) in clear detail with the 24L ultra-high frequency transducer. SMI is a Toshiba unique Doppler method for delineating low velocity blood flow in high resolution and in real time. The 24L is excellent for visualizing low velocity flow in minute vessels and SMI in Aplio i-series provides an even higher resolution and more penetration (Figure i, j).

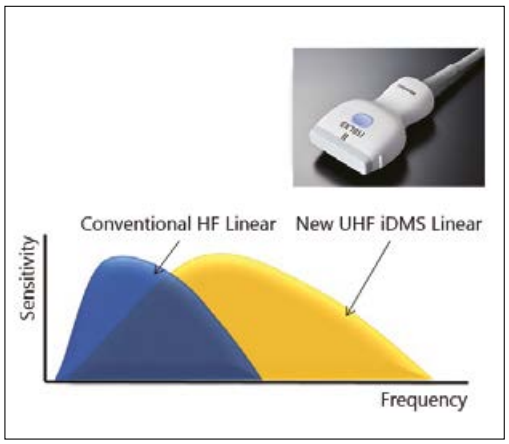

Figure 11: Ultra-high frequency

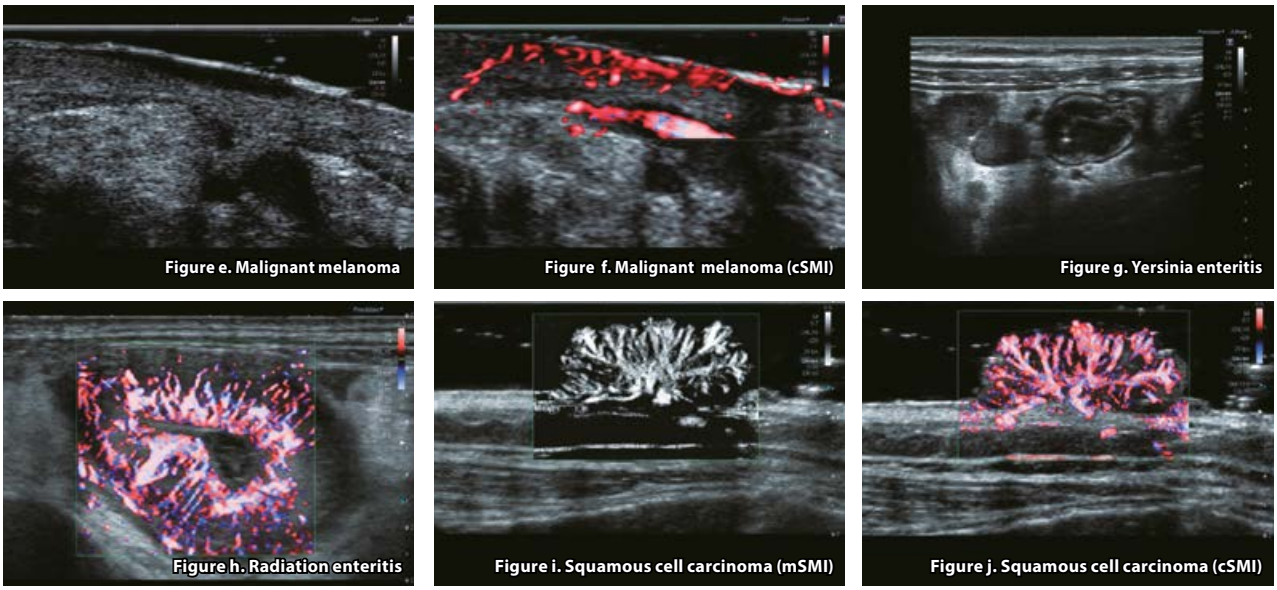

Figure 12. Courtesy of Professor Jiro Hata, MD.

Detail information about vasculature in deeper regions can be obtained and the use of SMI can be further expanded. I believe that knowledge about diagnosis and pathology can be increased based on these new capabilities. I strongly believe that there will be dramatic changes in every clinical region. "

Multiplexing Technology

Multiplexing technology is capable of handling large volumes of data at high speed, which allows parallel processing of multiple advanced operations. Controlling the elements of the new iDMS transducers requires 2-3 times more computing capacity compared to conventional transducers. In addition, increased volumes of receiving signal data, caused by real-time processing of complex clinical applications, make powerful parallel signal processing technology essential.

The extraordinary power of parallel signal processing allows execution of different advanced applications which need huge computational performance, such as Quad View, Shadow Glass, Smart Sensor 3D.

Professor Fuminori Moriyasu, MD.

Center for Cancer Ablation Therapy, International University of Health and Welfare, Sanno Hospital, Japan

"Fusion imaging is really important for ultrasound-guided RFA. The new Ultrasound-Ultrasound (US-US) fusion function on Aplio i-series offers easy-to-use and accurate orientation information to assist RFA (Figure k).



Figure 13. Multiplexing technology

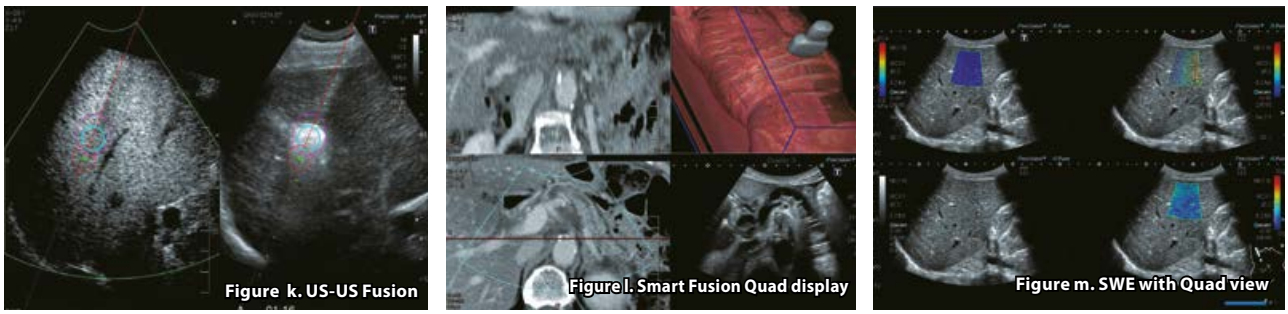

Figure 14. Courtesy of Professor Fuminori Moriyasu, MD.

Another new advantage of Aplio i-series is the Quad display for Smart Fusion which presents CT/MR volume images, 3D body mark, US image, and blended US & CT/MR image respectively. The location of the transducer and the position of B-mode in relation with the volume is clearly demonstrated in the 3D body marker. This gives a clear understanding of 3D orientation (Figure l).

In shear wave elastography, a real-time propagation map, speed map, elasticity map, and B-mode image can also be displayed in Quad View, providing an intuitive overview for easy selection of ROI. Measuring using One-Shot acquisition delivers accurate, reproducible and reliable data for quantitative analysis. I believe that it will be widely used for diffuse liver disease, focal liver disease and other clinical regions (Figure m)."

Professor Jiro Hata, MD.

Dept. Of Clinical Pathology and Laboratory Medicine, Kawasaki Medical School, Kurashiki, Japan

"With Aplio 500, 3D images can be reconstructed using 2D transducers and Smart 3D. With 3D SMI, the entire vasculature in an area of interest can be visualized, potentially allowing more effective surgical planning and treatment evaluation. Now, with Aplio i-series, 3D images with accurate positioning information can be acquired by utilizing Smart Sensor 3D technology. By adding this orientation data, measurements on 3D SMI volumes can be performed and accurate surgical planning is possible (Figure n).

One of Aplio i-series' new features for volume rendering is Shadow Glass. 3D semi-transparent volumes are reconstructed to observe tissue outlines (Figure o). These volumes can also be combined with 3D color images of vascular flow. This allows clear understanding of tissue in relation with location of vessels which is helpful for accurate surgical planning."

Volume Matrix

Aplio i-series' volume matrix transducers enables real-time volume imaging by steering the ultrasound beam in three dimensions. Volume matrix is based on 2D array transducer technology, combined with iDMS and Multiplexing architecture. Compared to conventional mechanical 4D transducers, volume matrix is superior for its high rendering power and flexible scan control, creating 4D images at higher volume rate and in multi-plane display.

Associate Professor Yoshihiro Seo, MD

Cardiovascular Division, University of Tsukuba, Japan

"The new 3D TEE volume matrix transducer is really small and light. The small acoustic head improves patient comfort. In addition, high resolution real-time 3D images can be acquired. The movement of mitral valve and aortic valve, or heart disease such as mitral valve prolapse can be observed easily (Figure p, q).

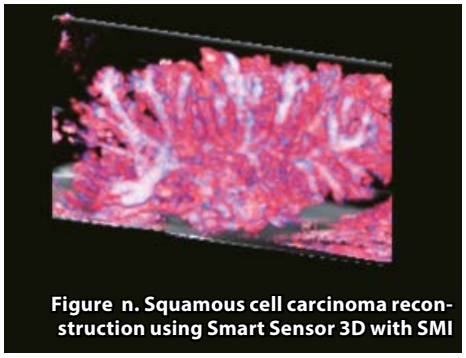

Figure n. Squamous cell carcinoma reconstruction using Smart Sensor 3D with SMI



Figure o. 3D reconstruction of fingers using Shadow Glass

Figure 15. Courtesy of Professor Jiro Hata, MD.

Figure 16. Volume matrix transducer



Figure 17. 3D beam steering

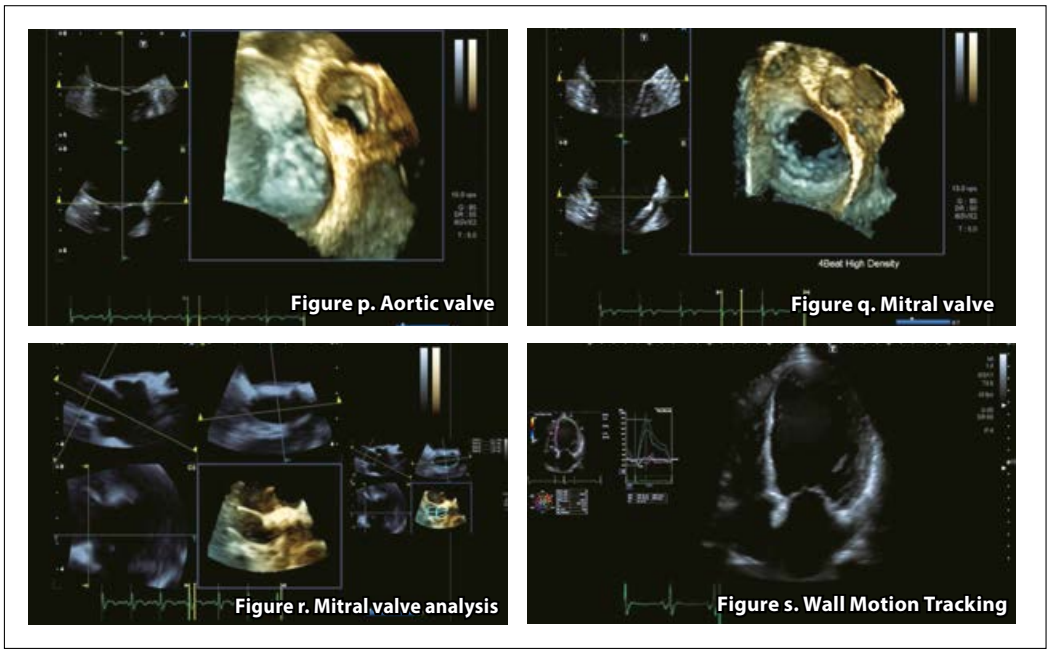

Figure 18. Courtesy of Associate Professor Yoshihiro Seo, MD.

Also helpful is the online 3D Mitral valve analysis software which is available for Aplio i-series. The MV analysis is really useful for clinical diagnosis and follow-up (Figure r). The accuracy of wall motion tracking by Toshiba was already superior, but got even better with the i-series. Strain measurement is highly accurate and the workflow for trace line is outstanding. I am very happy with the reduced analysis time and the reduction of inter-operative errors. (Figure s) "

CONCLUSION

Toshiba's Aplio i-series is both an evolution and revolution for system architecture and transducer technology, driving image quality to a new level. The highly improved image quality and advanced applications, innovative transducer technology and advanced ergonomic design of the Aplio i-series provide healthcare professionals more clinical confidence and increased clinical capabilities.

Aplio *i-series*
Intuitive. Intelligent. Innovative.

Musculoskeletal MRI in Football Medicine – essential, useful or too much information?

Dr Steve McNally [1)]

In the higher echelons of professional football, where financial resources are greater, the use of MRI as a diagnostic aid has been prevalent for the past 20 years. However, it has not always been employed as part of a validated clinical process with scans being requested sometimes for political reasons or simply in response to player/coach demand. The potential ramifications of MRI findings can go far beyond clinical management and affect transfer fees, player asset value, contract terms and conditions, insurability and medicolegal matters.

Dr Steve McNally

Radiologists reporting 'abnormal' findings can have detrimental effects on player wellbeing or confidence (or that of his/her therapist) leading to over-caution in training or rehabilitation and subsequent reduction in performance or athletic development. Clinical experience and scientific research show that many such 'abnormal' findings are in fact adaptive or developmental in response to the physical and biomechanical stresses of the sport and whilst they need to be recorded and noted once a player has been subjected to MRI examination, the interpretation by the referring practitioner is key as is subsequent communication to the player.

When interpreted within context by experienced sports physicians, therapists and radiologists working as a team, MRI can add great value if applied at appropriate times and situations as an adjunct alongside good clinical management. The advent of newer MRI techniques has increased diagnostic and screening/profiling possibilities and the development of functionally relevant protocols and sequences could enhance player care even further. Caution will be needed in how imaging information may be interpreted and potentially misused by those with business interests rather than patient welfare. This article will give an overview of musculoskeletal MRI as utilised in professional football though MRI is also becoming more widely used in the assessment of players from a cardiological and neurological perspective.

CLINICAL RELEVANCE

Injury diagnosis

The majority of clinicians in professional football will not refer a player for MRI in the early stages of injury assessment partly because it is unlikely to change their immediate clinical management and also because their budgetary resources will not permit it. Amateur and recreational players are only likely to be referred for MRI if they have a significant injury and have been referred on to secondary care specialists such as orthopaedic surgeons.

Conversely, at top professional levels there is often increased pressure from the player and the manager/coach to give an immediate prognosis for an injury ('when will I be back, Doc?') and MRI has become fashionable as having a key role in that diagnostic and prognostic decision-making process. I have experienced situations where players have demanded a scan within minutes of leaving the pitch with muscle pain and whilst there are some infrequent indications for early MRI following a significant trauma it is often better to wait for the clinical picture to evolve and to allow the necessary physiological response to injury to occur in order that MRI can detect relevant pathological findings (oedema/haemorrhage, etc.). The timing and sequences applied will therefore depend on many factors such as player age, nature of trauma, time since trauma and suspected tissues involved. Player and coach education in these aspects is important as a means of managing the immediate situation which understandably causes anxiety in highly driven and motivated individuals who will be anxious about future results, performances, careers and the financial and

[1)] *Head of Football Medicine & Science Manchester United, United Kingdom.*

Figure 1: Coronal oblique PD FS image of a 17 year old footballer's pelvis showing typical functional stress-related bone oedema in the pubic body bilaterally.

personal implications of an injury. The more widespread use of ultrasound scanning by sports team physicians over recent years has been very helpful in appeasing players/coaches and in alleviating such anxieties whilst also being clinically useful as it is easily applied, relatively cheap and allows daily monitoring of injury evolution. MRI added to that combination at the right time with the right sequences and the right interpretation within context is often very valuable.

JOINTS (BONE, CARTILAGE LIGAMENT)

Traumatic injuries to the knee, ankle and midfoot joints are very common in football, predominantly in the form of ligament sprains/ruptures; overuse injuries can affect those joints but also the lumbar spine, hips and pubic symphysis. Shoulder, elbow and wrist injuries are less common but are often significant when present, including dislocations, subluxations, fractures and loose bodies. Whilst X-rays still play a role as the primary investigation for the suspected fracture and ultrasound can be of use in superficial bony and ligamentous lesions, MRI is the go-to modality for the complete assessment from an imaging perspective in joint injury, particularly if there is associated joint swelling (effusion or haemarthrosis) and/or clinical signs of instability.

As football is an inherently 'traumatic' sport in terms of mechanical joint loading and from contacts with the ball and other players, a diligent radiologist will report many 'positive' findings on MRI scans many of which may be noted but disregarded by the team physician when evaluating a player. Many such MRI findings represent normal adaptation responses to the demands of the sport or the stage of skeletal maturity of the player and are not necessarily pathological. Examples include transient marrow oedema in the pubic bones of an adolescent player (Fig. 1) or thickening of the medial collateral ligament of the knee in response to repetitive kicking and tackling actions. Other findings previously thought to be less significant radiologically such as 'bone bruises' following contact trauma are now taken more seriously and have been re-termed as micro-trabecular fractures in recognition of the underlying pathology (Fig. 2).

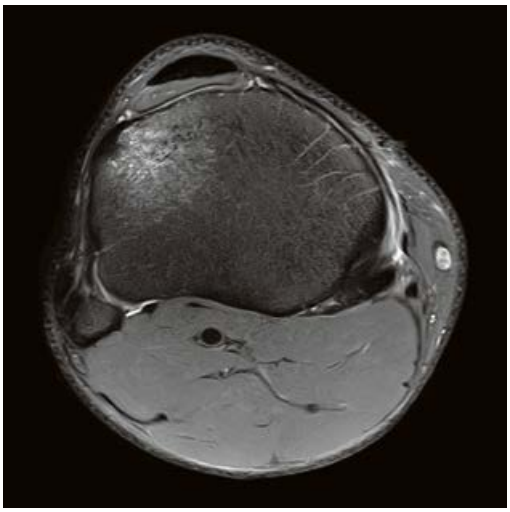

Figure 2: Axial PD FS image of a footballer's right knee showing a bony contusion in the medial proximal tibia due to a stud impact injury.

In my experience, MRI appearances 'over-grade' the severity of superficial ligament injuries when compared to a combination of clinical and ultrasound examination findings. Nevertheless MRI is essential to confirm the severity of deeper or internal joint ligament injuries such as knee cruciate ligament injury, particularly if the clinical signs are inconclusive (Fig. 3). MRI is the gold standard for imaging articular cartilage and meniscal cartilage injury, both of which may be acutely traumatic or chronically degenerative in origin in footballers or may occur in combination with ligament injury (Fig. 4). Bone marrow oedema on T2 or STIR sequences may indicate metabolic activity in an injured region such as the pars interarticularis of a lumbar vertebra or proximal shaft of a 5th metatarsal bone in the foot (common stress fracture sites in footballers). Marrow oedema may persist long after functional recovery and bone loading capacity has returned so its presence must not be the sole arbiter of a return to training activities (Fig. 5).

CT scanning has some advantages over MRI when assessing certain bone and joint injuries and both may be needed in combination to fully evaluate a hip impingement or lumbar spine stress fracture. The increasing image resolution afforded via 3T MRI imaging, however, is of great value when safely screening or profiling young footballers for anatomical factors that might predispose

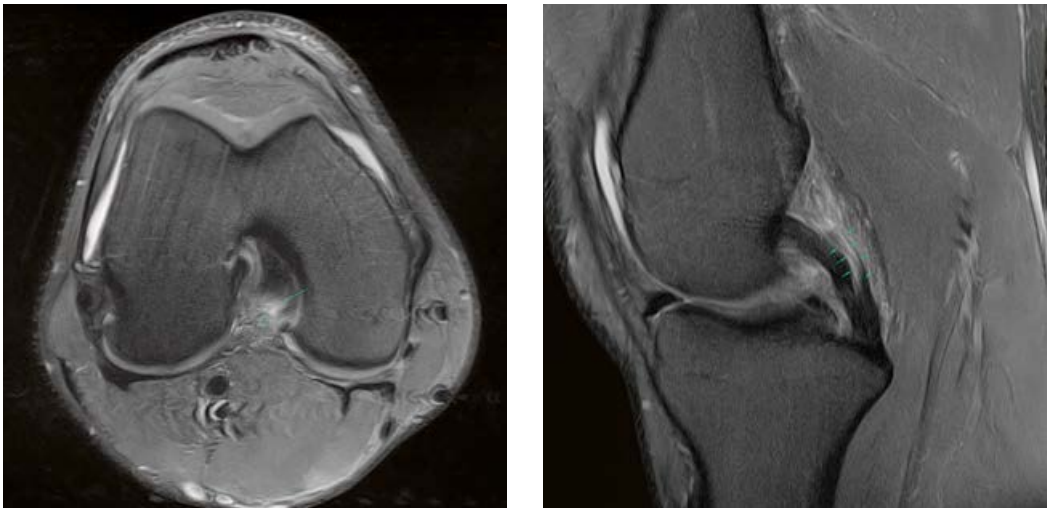

Figure 3: Axial & sagittal PD FS images of a footballer's right knee showing subtle oedema in the posteromedial bundle of the posterior cruciate ligament in keeping with a grade 1 sprain (green arrows).

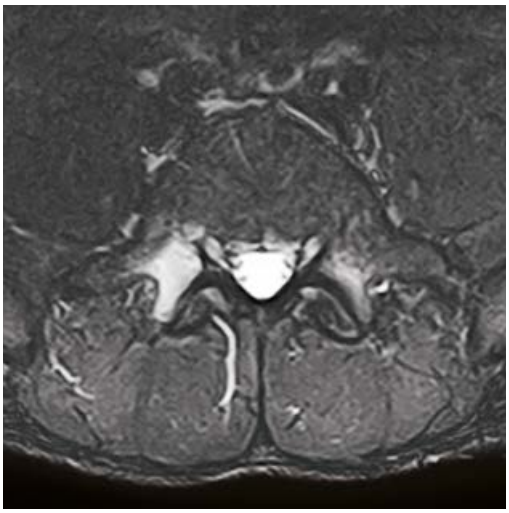

Figure 4: Axial STIR images of the 5th lumbar vertebra in a 20 year old footballer showing bilateral bone marrow oedema in the pars/pedicle region preceding eventual stress fracture formation.

Fig. 5: Localised residual oedema in the same player's right pars/pedicle region 8 months later (2 months after a return to full training).

them to typical football injuries, e.g. hip adductor muscle strains associated with pubic symphiseal or sacroiliac degeneration or CAM/pincer-type hip dysplasia (Fig. 6).

MUSCLE/TENDON

MRI is most useful for differentiating between the 'MRI-positive' (i.e. oedema, haemorrhage +/- structural disruption) and the 'MRI-negative' (i.e. no oedema, haemorrhage or structural disruption). High resolution ultrasound scanning in combination with clinical history and examination is sufficient in most cases to confirm structural injury but can be less helpful in confirming a functional injury where subtle muscle oedema may be present. MRI can be 'over-sensitive' with regard to muscle oedema causing dilemmas for the treating practitioner when determining the pathological from the normal reactive increase in lymphatic and vascular fluid post-exercise.

Timing of MRI examination after clinical presentation is therefore important. 24 to 48 hours is generally accepted as sensible practice to reduce the risk of false negatives or positives by scanning too soon. The widely used Peetron's grading system to describe muscle oedema and structural disruption is being superseded by alternative classification systems bespoke to athlete muscle evaluation as they are deemed to be more specific or relevant to clinical decision making. These include classifications based on MRI appearances alone[1] or those based on combining clinical presentations and examination findings with ultrasound and/or MRI appearances[2] (Fig. 7 & 8).

Debate exists as to the validity of MRI in determining key factors for the player, therapist and coach such as prognosis and return to play decisions[3,4] and there is no doubt that injured muscles can remain 'MRI-positive' for some time after functional recovery and return to play has been achieved[6]. Whilst the scientific research may not always be conclusive, experiential practice supports the use of MRI for accurate anatomical location and structural integrity assessment in key muscle injuries such as quadriceps, hamstrings and calf as the information gleaned can influence rehabilitation programmes in order to restore full performance whilst minimising re-injury risk. MRI may be the only way of identify deep groin/pelvic muscle injury in footballers that is beyond the depth of view of ultrasound scanning.

Footballers' tendon injuries are readily amenable to assessment by ultrasound in view of their relatively superficial location (patellar, Achilles, peroneal, tibialis posterior being those most often affected). The higher spatial resolution, the ability to assess dynamically and with Doppler/Microvascular Imaging and Elastography/Tissue Characterisation make ultrasound the modality of choice in most cases but MRI can add value when assessing the musculotendinous junction particularly if structural injury is very subtle or when examining longer tendons that follow a convoluted course (e.g. peroneus longus/flexor hallucis longus). Newer MRI techniques (ultra-short TE sequencing) may begin to tilt the balance more in favour of MRI.

Figure 6: Coronal PD FS image of an 18 year old footballer's left hip showing CAM-type femoral head configuration with associated labral tear from repetitive impingement during kicking and running actions. Note the presence of pubic symphiseal degenerative changes, a common associated finding.

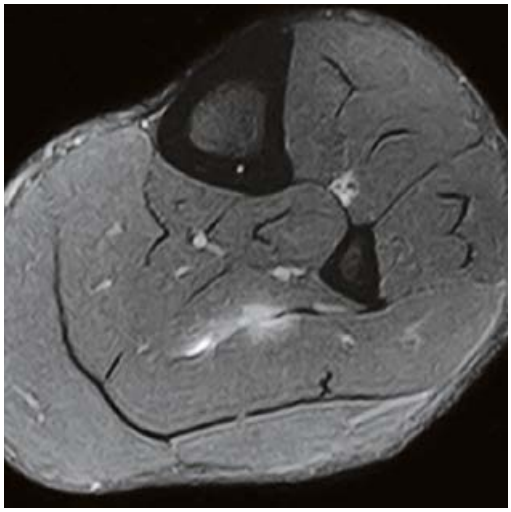

Figure 7: Axial PD FS image of a footballer's left calf muscle showing subtle oedema in the deep lateral soleus musculotendinous junction consistent with minor functional or very low grade structural injury.

SCREENING/PROFILING

It is difficult in many clinical settings to justify the use of MRI as a screening tool if the word 'screening' is utilised correctly within context of the Wilson-Jungner criteria (see below).

1. The condition sought should be an important health problem.
2. There should be an accepted treatment for patients with recognized disease.
3. Facilities for diagnosis and treatment should be available.
4. There should be a recognizable latent or early symptomatic stage.
5. There should be a suitable test or examination.
6. The test should be acceptable to the population.
7. The natural history of the condition, including development from latent to declared disease, should be adequately understood.
8. There should be an agreed policy on whom to treat as patients.
9. The cost of case finding (including diagnosis and treatment of patients diagnosed) should be economically balanced in relation to possible expenditure on medical care as a whole.
10. Case finding should be a continuing process and a not "once for all" project.

In an elite football club setting, however, the relative definitions of terms such as 'important health problem' and 'economically balanced in relation to medical care as a whole' will be viewed differently and MRI becomes a more acceptable screening tool for certain conditions. In reality there is insufficient scientific evidence to meet some of the other criteria such as 'latent/asymptomatic early stages' and 'recognised treatment pathways' and the players expect their healthcare and performance optimisation to be managed on an individual basis albeit within a team 'population' setting. In view of that I prefer to avoid the term 'screening' and replace it with 'profiling' as that enables the individual player to be compared to himself over time (injury surveillance) or against a group which can be defined in many ways (age, ability, playing position, etc.). MRI can be a powerful addition to all the other aspects of health and performance profiling that medical & science professionals can undertake on footballers.

Examples of such profiling include body composition assessment, muscle length, cross-sectional area and volume, skeletal maturity that can be specific to areas relevant to football such as pelvis and knee joints as opposed to standardised wrist imaging for skeletal age estimation. Emerging techniques utilising 3T MRI can assist with profiling muscle fibre type and joint cartilage composition via non-invasive means which makes the assessment very acceptable to the athlete patient.

Since access to players for screening/profiling purposes can be difficult to obtain, having a dedicated MRI facility close to hand is essential. However, there is usually one opportunity to profile a player when he/she joins the club (although the nature of the transfer system can also make that very difficult at times).

THE 'SIGNING/TRANSFER' MEDICAL

The common perception portrayed by the media is that footballers either 'pass' or 'fail' their transfer medicals when joining a new club. As there are no legislative or

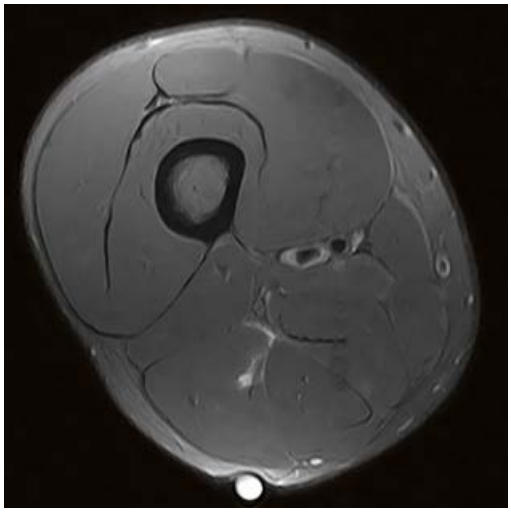

Figure 8: Axial PD FS image of a footballer's right thigh showing a localised structural defect at the biceps femoris musculotendinous junction with high signal extending from that into the myofascial space consistent with a moderate partial muscle tear (Munich Classification Type 3B).

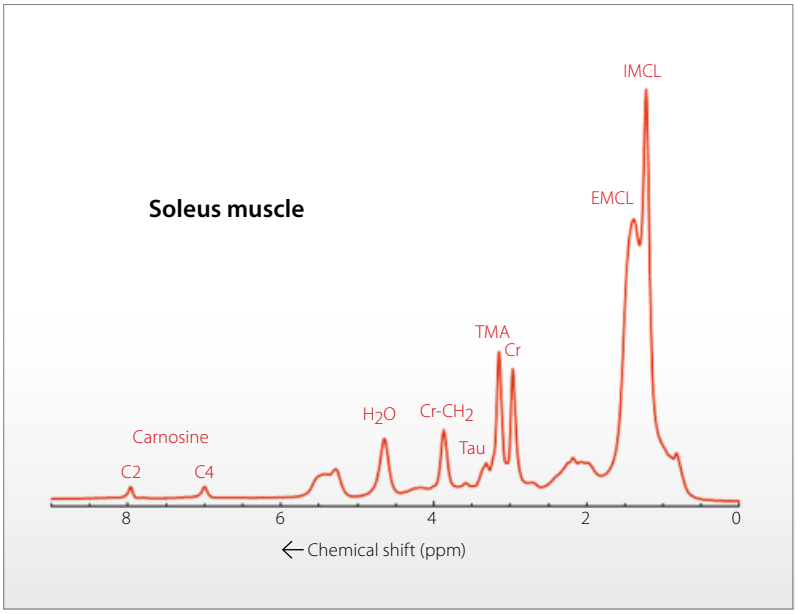

Figure 9: Spectroscopy of soleus muscle to assess carnosine content as an indicator of type 2 'fast-twitch' muscle fibre proportion.

industry-defined criteria for fitness to play professionally this is not strictly true. Each scenario will be different depending on the context of the transfer and this might be influenced by the duration of the proposed contract, the size of the transfer fee, the terms and conditions of the contract and financial aspects such as salaries and agent's fees. The process is more one of risk assessment and an opportunity to gather baseline information in order to assist with the player's subsequent medical care should he/she join the club. Whilst a transfer medical can be likened to a pre-employment medical where the initial duty of care is to the employer, a duty of care is also assumed towards the player whether he eventually signs or not, particularly if adverse findings are detected. MRI scanning can therefore be very informative but also fraught with ethical and medicolegal issues in such circumstances.

One of the major limiting factors in transfer medicals is time available, particularly if it takes place near the end of the transfer window periods. MRI scanning is usually the most time- consuming aspect of the medical assessment, even if limited sequence protocols are employed, and it might be impossible to include MRI if a transfer takes place in the final hours of 'deadline day'. Wherever possible it is our policy to include a limited sequence protocol examining lumbar spine, pelvis, hips, knees and ankles with additional sequences if clinically indicated from history and physical/functional examination. The scanning time needed is around 2.5 hours plus any transport time if this has to be undertaken at a remote facility. It's a long time for a player to be on the scanner table so maximising comfort and minimising sequence time is essential for full compliance and a positive 'first experience' for the player at his/her intended new club.

Although there is no consensus amongst football medics regarding the value of transfer medical MRI and many medicals take place without them being performed, it seems logical that the more information one is aware of when investing in a high value player the better, especially with regard to the detection of asymptomatic or subclinical pathology. Evolving articular cartilage lesions in joints or painless degenerative tendinosis might not cause a problem but could also be performance-limiting and potentially career-threatening; knowing about their presence in advance can help by modification of training loads and initiation of preventative programmes as part of asset management. MRI provides a baseline checkpoint which can be referred back to for comparison if needed.

As decisions, risk assessments and recommendations are usually required immediately after completion of the medical examinations it's vital to have experienced radiologists available 24/7 to report and discuss within clinical and functional context. In high value transfers it is not unusual to undertake 'double reporting' to seek a range of unbiased opinion.

'PERFORMANCE' IMAGING

In addition to standard anatomical MRI, post-processing applications can visualise structures in a more impactful manner (e.g. fat and lean mass) and quantify muscle tissue dimensions and volume. This can be very important for monitoring results of conditioning or rehabilitation programmes when comparing the player to him/herself or to a population of players who have been profiled in a similar manner.

MRI spectroscopy can be utilised to measure amounts of substances key to muscle function or fibre type composition, e.g. carnosine content is closely related to the proportion of fast-twitch fibres a player has within the muscle[5]. This can have implications for his/her genetically-determined performance potential, prescription of training programmes and recovery strategies post exercise (Fig. 9).

Compositional assessment of joint cartilage[7] is an exciting new development for football medicine as it has the capacity to detect microstructural and biochemical changes within the articular cartilage before eventual structural defects become apparent on standard MRI. Whilst many players are able to play professionally with established articular cartilage defects this pathology is one of the major career-limiting factors for a footballer if hip, knee or ankle are affected. Even if able to play without recurring joint pain, swelling or mechanical dysfunction, secondary injury or performance impairment is likely due to associated muscle inhibition or protective hypertonicity. The ability to detect pre-symptomatic changes in the cartilage by quantitative T2 mapping may facilitate early implementation of preventative strategies thereby prolonging athletic performance and the long-term health of the joint beyond the playing career.

1.5T V 3T

Although scanning with a 3T rather than a 1.5T scanner will not alter the subsequent clinical management in the majority of cases of typical football injury[8], 3T does offer advantages in terms of reduced scanning time (and hence patient comfort and acceptability). If time is no issue, better image quality is possible particularly for smaller joints such as the foot or wrist where subtle ligament or joint injury might otherwise go undetected. The radiographer and radiologist will need to amend their 1.5T techniques and some time may be required to fine-tune a 3T scanner to the area under examination. The effort will be worthwhile leading as it leads to beautiful images. Findings that previously were impossible to detect need to be interpreted carefully in

conjunction with the treating sports physician. Another advantage of 3T MRI in the sports medicine setting is that emerging technologies such as those described above for performance profiling are more readily applicable in higher field strengths.

SUMMARY

As the physical demands of professional football and the financial investments in the industry continue to increase year on year, the pressure on club medical & science teams to maintain their players in top condition also increases. Some injuries are inevitable and the aim then is to return the player to the pitch at the required performance level with minimised risk of re-injury in the shortest possible time. MRI has a role to play in that overall process and it will continue to evolve as technologies develop and practitioners become familiar and confident in applying them within this unique area of sports medicine.

References

1. Pollock N, et al. British Athletics muscle injury classification: a new grading system. Br J Sports Med 2014; 48:1347–1351. doi:10.1136/bjsports-2013-093302
2. Mueller-Wohlfahrt HW, et al. Terminology and classification of muscle injuries in sport: a consensus statement. Br J Sports Med 2012;0:1–9. doi:10.1136/ bjsports-2012-091448
3. Ekstrand J, et al. MRI findings and return to play in football: a prospective analysis of 255 hamstring injuries in the UEFA Elite Club Injury Study. Br J Sports Med 2016;0:1–7. doi:10.1136/bjsports-2016-095974
4. Wangensteen A, et al. MRI does not add value over and above patient history and clinical examination in predicting time to return to sport after acute hamstring injuries: a prospective cohort of 180 male athletes. Br J Sports Med 2015; 49:1579–1587. doi:10.1136/bjsports-2015-094892
5. Baguet A, et al. A New Method for Non-Invasive Estimation of Human Muscle Fiber Type Composition. PLoS One. 2011;6(7):e21956. doi: 10.1371/journal.pone.0021956
6. Reurink G, et al. MRI observations at return to play of clinically recovered hamstring injuries. Br J Sports Med 2014; 48:1370–1376. doi:10.1136/bjsports-2013-092450
7. Guermazi A, Roemer FW. Compositional MRI assessment of cartilage: what is it and what is its potential for sports medicine? Br J Sports Med Aug. 2016 Vol 50 No 15
8. Roemer FW, Guermazi A. What is the role of 3T MRI in sports medicine? Revisiting the marriage after the honeymoon. Br J Sports Med, Aug. 2016 Vol 50 No 15

Seeing the un


Hepatocellular carcinoma

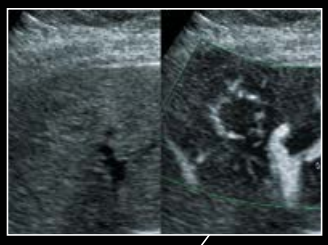
Hemangioma


Normal kidney

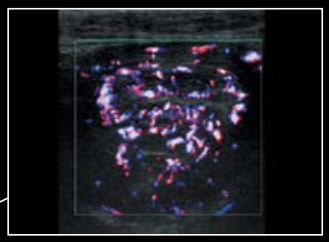
Stomach carcinoma

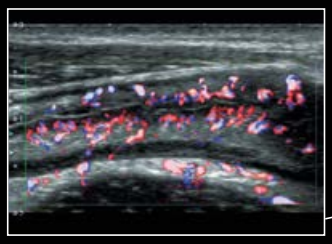
Crohn's disease


Endoleak


Prostate

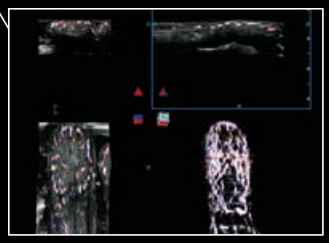
Finger tip


Testis

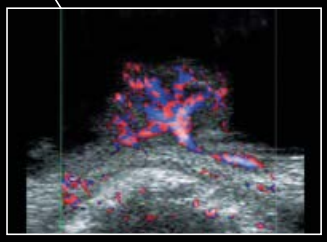
Bladder carcinoma

"SMI provides a non-invasive and pain-free method for detecting vesicoureteral reflux in young patients. In addition, SMI offered a more rapid diagnosis and does not require radiation exposure to young patients, as compared with cystography."

Professor Sara M. O'Hara
Department of Radiology and Medical Imaging, Cincinnati Children's Hospital Medical Center, U.S.A.


VUR detected within the renal pelvis

seen with SMI

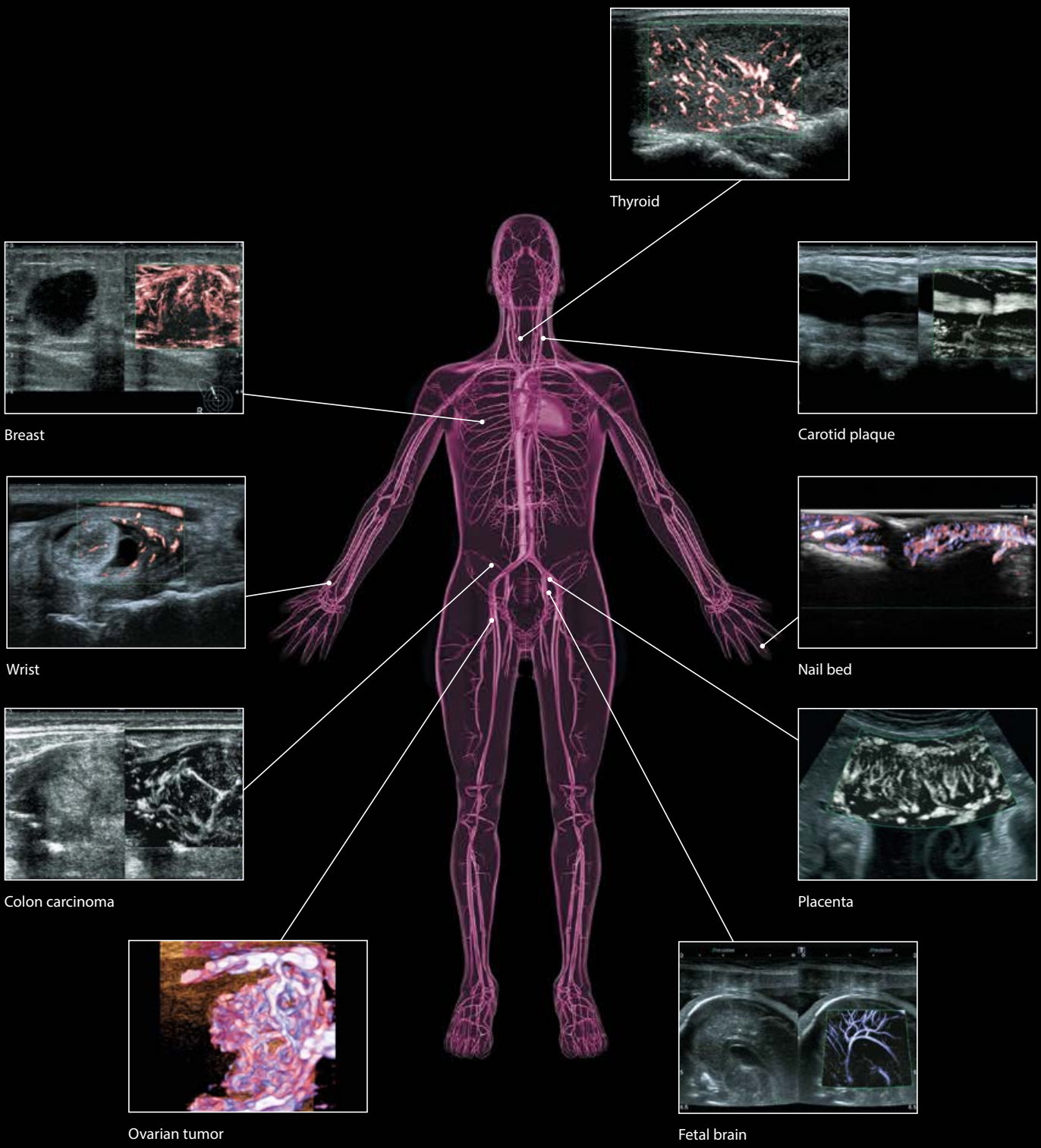

"Assessment of the fetal heart in the first trimester is challenging, even for experienced doctors. For this reason it is important to find ways to improve the visualization of the cardiac structures. This is exactly what SMI does! It shows the cardiac structures in a more clear way."

Dr. Jader Cruz
Centro Hospitalar Lisboa Central, MAC, Portugal

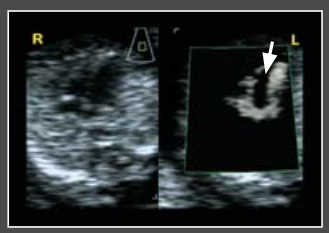

Interventricular septum in 4 chamber view

TÜV Confirms Low Energy-Consumption Figures for the Aquilion PRIME

Saving Energy Means Saving Costs as well as Contributing to a Better Environment

As energy costs continue to rise, energy-consumption in large equipment is an increasingly important subject for detailed discussion - not just in terms of the environment, but also in cost-saving. Machines that use less energy can save money. A lot of money.

Toshiba Medical's CT Development Department sets the benchmark - energy efficiency right at the top of its list of priorities. Its new CT machines are, therefore, not just low-dose systems, but also low-energy CTs.

As soon as Toshiba Medical's CT Development Department revealed the low energy-consumption values that its new machines could achieve, there was a great deal of surprise - No-one had anticipated that such a significant reduction in energy could be achieved. This was reason enough to get the information verified. Hence, the TÜV (Technischer Überwachungsverein or German Technical Inspection Association) was commissioned to carry out long-term assessments.

TÜV CONFIRMS LOW ENERGY-CONSUMPTION VALUES

The TÜV measured the actual energy-consumption, using the low-dose Aquilion™ PRIME CT machine as an example, and confirmed that the average consumption was only 3.5 kW (i.e. 84 kWh per day). CT machines of a comparable performance class made by other manufacturers require 6 – 12 kW (144 – 288 kWh per day), minimum 6 kW – almost double the energy.

In order to obtain a realistic value for the energy-consumption of a CT machine, which is comprehensively used in daily clinical practice with a high patient throughput, the measurement was carried out on the Benjamin Franklin Campus at the Charité University Hospital in Berlin, Germany, where the Toshiba Aquilion PRIME CT machine is in operation 24 hours a day.

HALVING ENERGY COSTS WITH THE AQUILION PRIME

The reduced energy intake is also obvious on resultant energy bills, as the following example shows: If you calculate average energy costs using 20 cents[1] per kilowatt hour, the annual energy costs for the CT machine total €6,062 incl. VAT (3.46 kW on average x €0.20 per kWh [incl. VAT] x 365 days per year x 24 hours). If a radiology department were to operate a 'comparable CT machine', but with twice the energy-consumption, the annual energy costs would be twice as high. Calculated over the average lifespan of the machine of eight years, the difference is almost €50,000. With a continued annual energy price increase of 5%, the difference is, in fact, almost €60,000.

€60,000 LESS IN ENERGY COSTS WITH A TOSHIBA LOW-ENERGY AQUILION PRIME CT MACHINE

As a proportion of the energy from the X-ray tube is converted into heat, which must be discharged, the real costs are significantly higher, as a cooling system has to be procured, as well as maintained and operated.

Beyond the pure consideration of costs, Toshiba Medical is particularly concerned with protecting the environment. The Toshiba Environmental Report[2], which can be found within the company's Corporate Social responsibility Report, emphasizes Toshiba Medical's commitment to environmental protection, through its description of the impressive measures that the company is implementing in its products, as well as its facilities.

148 TONNES LESS CO_2 THANKS TO THE LOW-ENERGY CT MACHINE

The low-energy Aquilion PRIME CT machine, however, not only reduces energy costs but also significantly reduces carbon dioxide emissions in particular: the achievable CO_2 saving over eight years amounts to 148 tonnes of carbon[3], if the CT machine only requires an

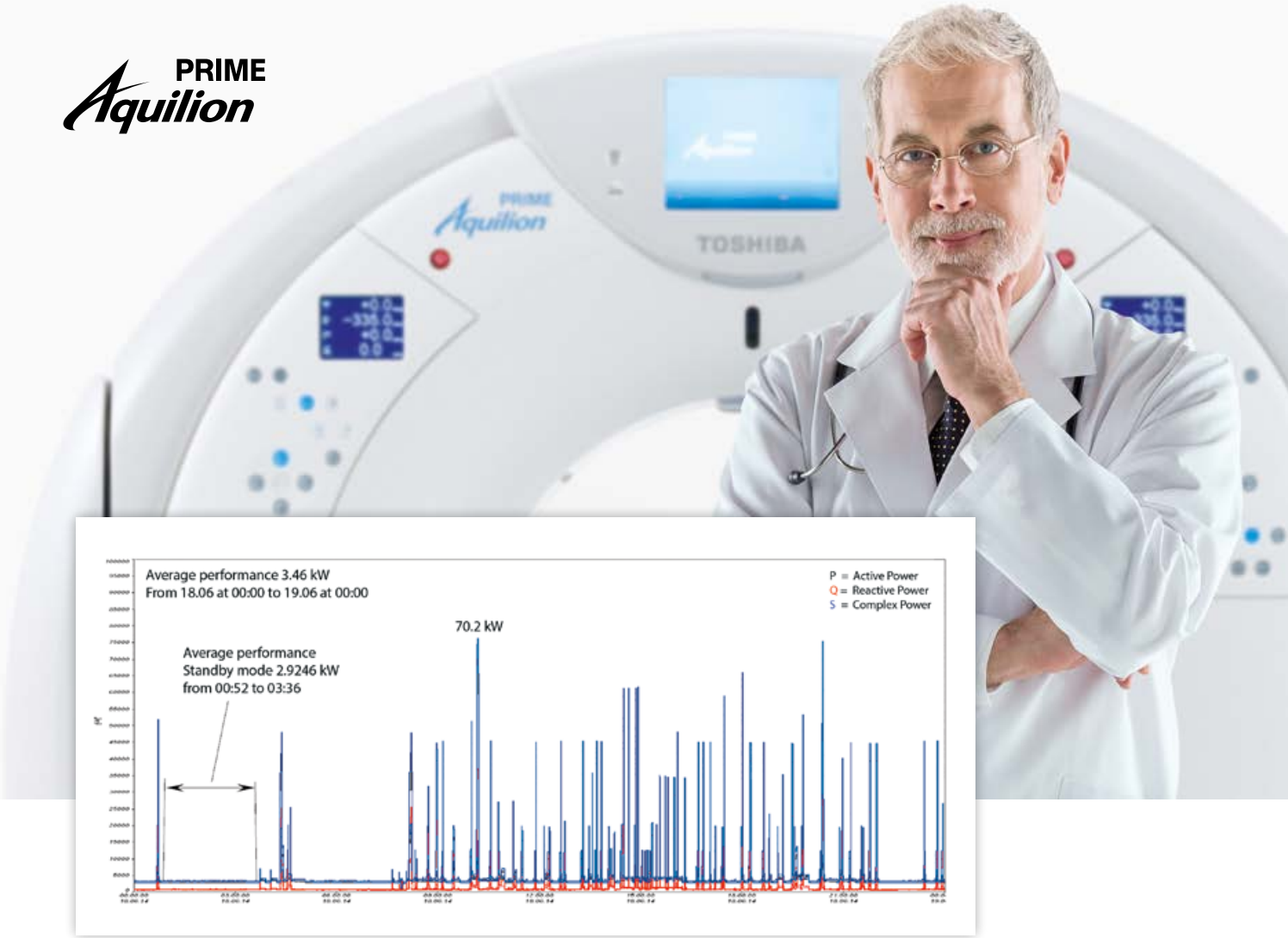

Figure 1: Power graphic

average of 3.5 kW power, and not 7 kW, like systems of a comparable performance class by other manufacturers.

ENERGY EFFICIENCY IS BECOMING A PURCHASING CRITERION

When assessing the price of the new CT machine to be procured, it is worth not simply looking at the value of investment and the annual maintenance costs, but also at energy-consumption energy costs. Over a lifespan of eight years, the right low-energy CT machine can easily save you over €60,000.

EVALUATION OF THE LOW-ENERGY AQUILION PRIME CT MACHINE BY THE TÜV

Over the course of a week, the energy intake of the Aquilion PRIME was measured by the TÜV and recorded; fig. 1 shows a typical work day, in which patients were examined continuously in the CT machine between 8 am and 10 pm. The CT machine was also used at night for urgent examinations. The average performance in standby mode was 2.9 kW; the average performance over the whole day was only 3.46 kW, not even 84 kilowatt hours (kWh). There are a number of reasons behind this particularly low energy intake. For example, the reduced tube power during the examination due to iterative dose reduction, with consistent image quality, as well as the energy management within the CT machine, including intelligent cooling, which only starts if the limit value is exceeded. In addition, the generator size, which is typically smaller in Toshiba CT machines than those from other manufacturers, is another reason why less energy is required to provide a diagnostic result. The particularly low energy intake of the Toshiba CT machine, therefore, ensures the optimization of the chain, from acquisition to reconstruction.

KFW SUPPORTS LOW-ENERGY CT MACHINES WITH LOWER INTEREST RATES

In addition, investments in large-scale machinery are supported by the KfW (a German government-owned development bank or credit institute) if they are particularly energy-efficient, more favorable loans are awarded for these systems. Experience to date shows that all Toshiba CT machines are energy-efficient and are supported by the KfW.

[1] 20 cents per kWh is a realistic average value. The costs per kWh may be dependent on region, supplier and type of contract, and may deviate from one to another.
[2] http://www.toshiba.co.jp/csr/en/report/download.htm.
[3] According to the CO_2 calculator from the Federal Environment Agency, http://uba.klimaktiv-co2-rechner.de/de_DE/page/mobility-road/.

Shear wave on Aplio 400 and Aplio 300

Toshiba Medical's Shear wave elastography is a highly reliable tool for daily routine scanning. Now we support Shear wave on an even wider range of diagnostic Ultrasound systems, making it more accessible to ensure you can provide the best possible care to your patients by utilizing the latest technologies for non-invasive tissue assessment. Our Shear wave elastography suite with unique smart maps will help you to make an accurate diagnosis, simpler and faster.

Shear wave now also available on **Aplio 400** Platinum Series **Aplio 300** Platinum Series

Transducers that broaden clinical capabilities

A selection of transducers that allow Shear wave to be used in a wide range of clinical areas including Abdomen, Breast, Thyroid, MSK, Endovaginal, Endorectal and more.


PVT-375BT/SC


PLT-1005BT


PVT-781VT/VTE

SHEAR WAVE ELASTOGRAPHY

Toshiba Medical's Shear wave technology provides a quantitative measure and dynamic visual display of tissue stiffness in a variety of clinical settings ranging from abdominal to small parts examinations. This highly accurate and reproducible tool provides fully integrated measurement and reporting for seamless integration into your clinical workflow.

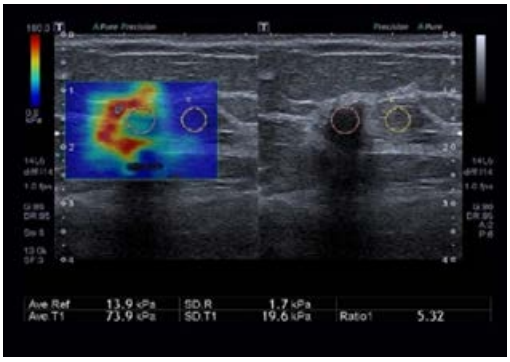

Invasive Ductal Carcinoma (IDC)

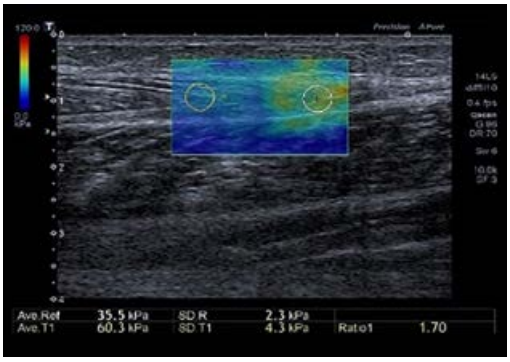

Muscle strain

** Images courtesy of Dr Adrian Lim, Charing Cross Hospital, London*

SMART MAPS

Aplio' s Smart Maps allow you to visualize and quantify Shear wave propagation in a user-defined region of interest in real-time. The user can select both dynamic propagation speed and elasticity displays for visual assessment and quantification.

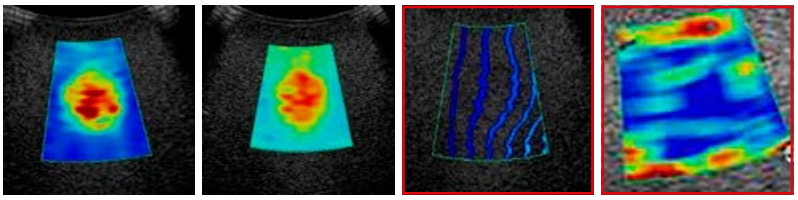

Unique | Unique

Speed [m/s] | *Elasticity [kPa]* | *Propagation map* (Arrival time contour) | *Variance map* (2D presentation of propagation)

PROPAGATION MAP

Aplio' s unique propagation map is a powerful and intuitive tool to visually assess the quality of an elastogram. Areas with distorted or absent Shear wave propagation are easily recognized by means of a disrupted wave front.



Good Acquisition | *Poor Acquisition*

** Images courtesy of Dr Adrian Lim, Charing Cross Hospital, London*

THE PRINCIPLE BEHIND SHEAR WAVE ELASTOGRAPHY

Shear waves are generated inside the human body by means of an ultrasonic burst (left). Depending on tissue stiffness, Shear waves travel at varying sp eed, but generally very slowly through the human body. Their propagation can be followed and visualized using conventional ultrasound imaging techniques (right). The propagation speed of the Shear waves directly correlates with tissue stiffness.

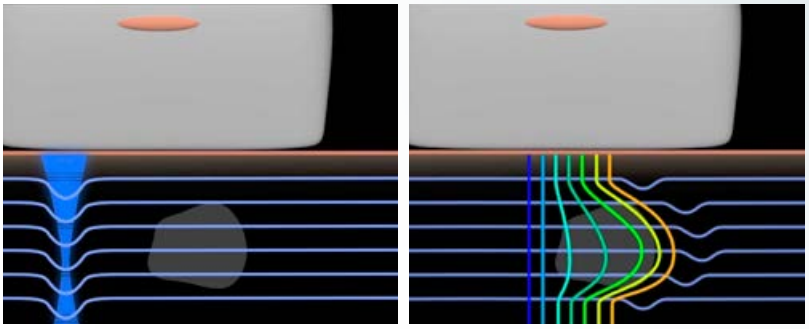

Staging of liver fibrosis

The intuitive propagation map is able to reveal wave patterns that are characteristic for each stage of liver fibrosis. Lines that are further apart indicate the propagation wave is travelling at a higher speed and therefore is moving through a harder tissue mass.

The propagation map also guides you in selecting a reliable ROI for taking accurate measurements and confirming your diagnosis by absolute values.

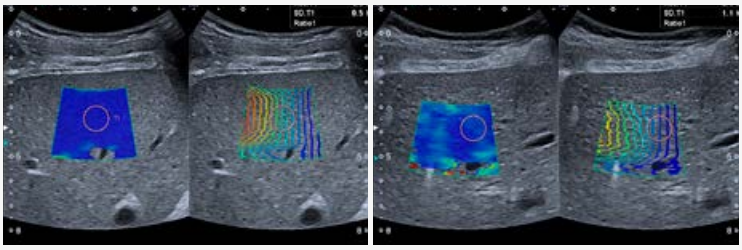

F1 | *F2*

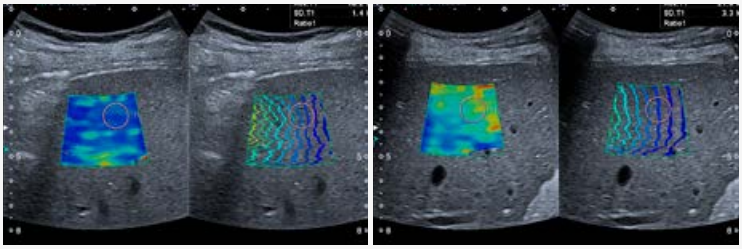

F3 | *F4*

** Images courtesy of Dr Giovanna Ferraioli, Prof Carlo Filice, University of Pavia, Italy*

TOSHIBA MEDICAL

Made For life

Are you aware of the peak skin dose of your patient?

Toshiba Medical's DTS (Dose Tracking System) is a unique feature that enables real-time visualisation of skin radiation dose of patients that are under examination or treatment. Knowing skin dose is particularly important as the length of interventional procedure increases, especially with adoption of advanced and more complex techniques. For the first time in history skin dose is presented real-time on a clear and easy to understand colour map visible to all health care professionals. DTS makes people-friendly care available to everyone involved in medical practice, including patients, doctors and other medical-care providers. DTS: A new era in dose management has arrived.

DoseRite™

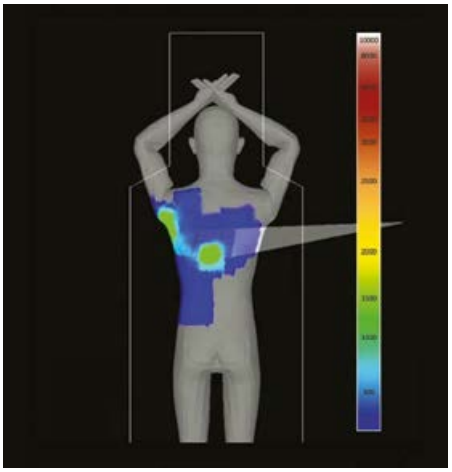

Skin dose is shown in real-time on an easy to understand colour map.

www.toshiba-medical.eu

TOSHIBA MEDICAL

Made For life

Register online for **VISIONS**

Stay up-to-date with the latest innovations in medical imaging

Subscribe to have access to full, previously published, digital editions of VISIONS Magazine. Visit our web site at: **www.toshiba-medical.eu/visions**

Do you also want to receive a paper copy of VISIONS magazine at home or at work? Please tell us so during registration and we will send you VISIONS magazine twice a year! Registration is easy and absolutely free.

Alternatively you can follow us at SlideShare (http://www.slideshare.net/toshibamedical) and dedicated VISIONS LinkedIn Group (https://www.linkedin.com/groups/3698045)

TOSHIBA MEDICAL

Made For life

ONE Aquilion
GENESIS Edition

GENESIS Edition – Transforming CT

Building on over 10 years of clinical experience in Area Detector Technology, Aquilion ONE GENESIS sets a new standard in delivering higher quality CT examinations for superior diagnostic confidence in a patient-centric and cost-conscious design.


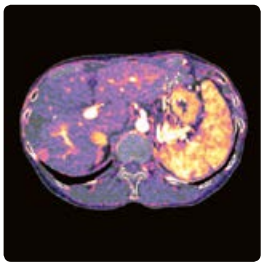


MADCT0001EUC