TOSHIBA MEDICAL

SPECIAL

VISIONS

Magazine for Medical & Health Professionals | March 2017

10 YEARS AHEAD
Area Detector CT

VISIONS | CT SPECIAL

10 YEARS AHEAD
Area Detector CT

This CT Special edition of VISIONS magazine is a publication of Toshiba Medical Europe and is offered free of charge to medical and health professionals. To download the digital edition of this CT Special, please visit the campaign web site: www.toshiba-medical.eu/eu/ct-campaign-10-years-ahead. No part of this publication may be reproduced in whole or in part, stored in an automated storage and retrieval system or transmitted in any manner whatsoever without written permission of the publisher. The opinions expressed in this publication are solely those of the authors and not necessarily those of Toshiba Medical. Toshiba Medical does not guarantee the accuracy or reliability of the information provided herein.

Publisher
Toshiba Medical Systems Europe B.V.
Zilverstraat 1
NL-2718 RP Zoetermeer
Tel.: +31 79 368 92 22
Fax: +31 79 368 94 44
Web: www.toshiba-medical.eu
Email: Marketing@toshiba-medical.eu

Campaign web pages: www.toshiba-medical.eu/eu/ct-campaign-10-years-ahead

Editor-in-chief
Jack Hoogendoorn (jack.hoogendoorn@toshiba-medical.eu)

Editor
Jacqueline de Graaf (jacqueline.degraaf@toshiba-medical.eu)

Coordinator & Reviewer
Roy Verlaan (International Market Development Manager CT)

Design & Layout
Boerma Reclame (www.boermareclame.com)

Photography
Cojan van Toor (www.cojanvantoor.nl)

Printmanagement
Het Staat Gedrukt (www.hetstaatgedrukt.nl)

Text contributions and editing
The Creative Practice (www.thecreativepractice.com)

FSC
www.fsc.org
MIX
Papier van verantwoorde herkomst
FSC® C021743

© 2017 by TOSHIBA Medical Europe
All rights reserved

ISSN 1617-2876

Follow us

EDITORIAL

"The Journey Continues"

Dear reader,

Sometimes, a journey is a necessity, and the development of the Aquilion ONE™ is one of those journeys. Many people throughout history with the spirit of an adventurer have decided to explore the unknown. Most journeys, just like the development of the Aquilion ONE, take us to places we have not seen before and provide previously unseen insights.

Driven by the clinical need for a CT scanner that was able to combine both functional- and morphological information, was where Toshiba Medical's journey started. Combined passion, craftsmanship and accuracy were the buildings blocks in the development of the Area Detector CT that resulted in the introduction of the Aquilion ONE in 2007. The Aquilion ONE and its unique Area Detector technique marked the next step in CT after Helical and Multislice CT Imaging. Together with groundbreaking hardware, it brought software that provided unique solutions for clinicians throughout the world, including arrhythmia scanning in cardiac patients, isophasic whole brain perfusion and 4D dynamic MSK scans.

It was the Aquilion ONE ViSION Edition, equipped with the PUREViSION detector, that marked the next step forward in Area Detector CT. Together with a faster rotation time and Integrated Iterative Reconstruction, AIDR 3D, access to even lower doses was provided.

The journey of the Area Detector CT continued, even after the introduction of the ViSION Edition, as Toshiba Medica has always been committed to innovation. This commitment has led to groundbreaking techniques that have been included in the latest Area Detector CT: the Aquilion ONE GENESIS Edition. Introducing the ease of X-Ray into CT, the latest PUREViSION Optics and Integrated MBIR, means that the Aquilion ONE GENESIS Edition transforms CT as we know it.

It has been 10 years since the introduction of the first Area Detector CT, and we would like to invite you to join us in celebrating this remarkable achievement. This VISIONS Special highlights personal experiences of Key Opinion Leaders. It outlines Toshiba Medical's journey in Area Detector CT and shows our continuing spirit to explore the unknown. The journey continues…

Kind regards,

Roy Verlaan
International Market Development Manager CT
Toshiba Medical Systems Europe BV

6 Toshiba Medical's Business Unit Manager CT, Henk Zomer, and Senior Product Manager CT, Henk de Vries, reflect on a decade of groundbreaking developments.

12 Professor Albert de Roos, Professor of Radiology at the LUMC explained how the scanner and partnership with Toshiba Medical has opened many doors, not only to new techniques and clinical possibilities, but also to important collaborations with other research experts across the world.

15 Publications 2007/2008

CONTENTS

©2017 TOSHIBA MEDICAL

"Area Detector CT is Toshiba Medical's flagship - our masterpiece of technology"

Henk Zomer,
Business Unit Manager
Computed Tomography

"Although in the future, further dose reduction will continue to be important, the values are already so low now that the amount of contrast used in contrast enhanced scanning is becoming as important as exposure dose"

Henk de Vries,
Senior Product Manager
Computed Tomography

©2017 TOSHIBA MEDICAL

Shaping the Future of CT

Developed following a request from clinical practice, the Aquilion ONE™ was hailed as 'a global breakthrough in CT' when it was first introduced in 2007. With its unique Area Detector, the new system brought physicians new opportunities in volume- and dynamic scanning and opened the doors to a new way of medical imaging. The Aquilion ONE's remarkable journey over the last 10 years has resulted in unique software- and hardware developments that have changed the direction of CT. Toshiba Medical's Business Unit Manager CT, Henk Zomer, and Senior Product Manager CT, Henk de Vries, reflect on a decade of groundbreaking developments.

DEVELOPED TO MEET CLINICAL NEEDS

When Toshiba Medical started with the Aquilion ONE series, the engineers focused on achieving a faster rotation as well as the key differentiator - scanning a wider field of view.

"Development of the Aquilion ONE originated from the clinical requirements of a Japanese Professor, who advised Toshiba for many years and shared our vision on optimizing imaging," said Henk de Vries. "Focused at that time on perfusion, he wanted to be able to scan complete organs without movement for better temporal resolution. With that request, our engineers in Japan started the development of an Area Detector."

"Up until then, scanning was hampered by the width of the detector. There are techniques, by which, people can move the table to an extent to enlarge the scan range, but this had limitations, because of temporal resolution. Toshiba Medical set out to overcome this and made a wide field of view that covers an organ in one go. That was actually the birth of the Aquilion ONE," added Henk Zomer.

A MAJOR BREAKTHROUGH

The first prototype was ready in 2000. Between 2000 and 2007 Toshiba Medical worked continuously on further improvement of the prototype, resulting in the launch of the first Aquilion ONE in 2007.

"When Toshiba Medical came out with the first Aquilion ONE, it was absolutely a major breakthrough, not only being the first Area Detector CT, but also in the software: the algorithms that were behind it. There was no other vendor who had something even close. And now, 10 years later, we are still ahead."

"When we received the first images from the Aquilion ONE prototype, the reconstruction times were extremely long. Initially, a special computer had to be used to reconstruct the data. The scanner was not ready for clinical use yet, but we were able to progress from there on. There was a great deal of research being done at that time about the issue of data processing and imaging, and the developments made by Toshiba Medical in developing the Aquilion ONE contributed to advancing this. Thanks to the vision, skills, dedication and passion of our engineers; they perfected the development of the new CT system."

UNFORGETTABLE EXPERIENCE

The clinical- and commercial introduction of the Aquilion ONE in 2007 was a landmark in Toshiba Medical's history that no-one at the company at that time will ever forget.

"I went to Japan just before the official launch of the Aquilion ONE, and attended a presentation on the new scanner," said Henk de Vries. "As I was sitting there, waiting for the presentation to start, I was sure that the new system would be a 256. Three slides into the presentation, the specifications came on - they said 320! I was flabbergasted: speechless for a while! Until then, this amazing fact had been secret. That was my personal highlight of the introduction. I will never forget it."

"It was really exciting!" remarked Henk Zomer. "We knew just a little about the developments going on in the background, but when Japan came out with the machine, the actual coverage of 16cm was absolutely astonishing! The initial information had indicated that the coverage would be 12.8cm. I remember telling the first Aquilion ONE customers, in the process of acquiring the very first machine, that the actual coverage would be 16cm. It was extremely encouraging and exciting. My personal highlight of the introduction of the Aquilion ONE was the reaction of our customers. They were already enthusiastic, but when they saw what really had been developed, they were amazed."

With the Aquilion ONE, it became possible for physicians to not only view a three-dimensional depiction of an organ, but also for the first time, dynamic blood flow, function and movements could be depicted by a CT scanner. Unlike any other CT system, the system provided the possibility to scan complete organs in one rotation, because it covers up to 16cm of anatomy using 320 high resolution 0.5mm detector elements.

"A group of experts from Leiden visited Japan and tested the new scanner," said Henk de Vries. "That was the first time I saw images, dose figures and the technical possibilities, and realized what the scanner could do. Experiencing something new that would change the world of CT and totally unknown to the rest of the world made the biggest impression on me."

ENTHUSIASTIC RECEPTION

Customers soon recognized the opportunities offered by Area Detector CT, particularly in cardiac scanning, which had proved cumbersome up until then. Some users found completely new applications using the Aquilion ONE and started for example to carry out research into the mechanics of joints.

"People discovered the range of new possibilities provided by the dynamic capabilities of the Area Detector CT, which continued to improve over time," said Henk Zomer.

"Early adaptors to the new technology, included Leiden University Medical Center, in the Netherlands, Charité University Hospital in Berlin, Germany, and the University of Nancy in France, are still very enthusiastic about the Aquilion ONE and continue to advise Toshiba Medical on possible new applications," added Henk de Vries.
There are now more than 1,200 Aquilion ONE CT systems installed worldwide. Many of our users provided feedback on possible further refinements, ultimately contributing to development of the latest system, the Aquilion ONE GENESIS.

FLAGSHIP TECHNOLOGY

"Area Detector CT is Toshiba Medical's flagship - our masterpiece of technology," remarked Henk Zomer. "A lot of the technology developed initially for the Area Detector appears in other machines in our product range - the reconstruction algorithms, the dose reduction algorithms, and elements of the detector technology can be found in our present range of CT systems, even down to our starting-level CT scanners. The Aquilion ONE has had and still has a large impact on the technologies used in our total CT product portfolio."

"The Aquilion ONE has opened markets for us," added Henk de Vries. "For example, Toshiba Medical's presence in University hospitals has increased dramatically since its introduction."

CONTINUAL DEVELOPMENT

Toshiba changed the direction of medical imaging with Area Detector CT, and has continued to respond to evolving user demands through constant development of software and hardware.

"Technology never stops," said Henk Zomer. "Development at Toshiba Medical is ongoing. With a fantastic team of engineers, and the feedback of very knowledgeable users, we will continue to make fantastic products that will evolve beyond today's level."

"Partnership with our users can lead to significant developments," added Henk de Vries. "Our latest addition to the Aquilion Family - The Aquilion ONE GENESIS – includes features that have been developed accordingly."

STRENGTHENING POSITION

Launched in November 2016, the Aquilion ONE GENESIS Edition strengthens and expands Toshiba Medical's leading position in Area Detector CT even further.

Henk Zomer
Business Unit Manager CT
Toshiba Medical Europe

Henk joined Toshiba Medical in 1985 as an application specialist Computed Tomography and Nuclear Medicine. In 1988, he was appointed as a Marketing Manager Computed Tomography and Nuclear Medicine, and has been Business Unit Manager since 1990.

©2017 TOSHIBA MEDICAL

Henk de Vries
Senior Product Manager CT
Toshiba Medical Europe

Henk joined Toshiba Medical in 1988 in Nuclear Medicine. In 1999, he was appointed Product Manager CT and focussed on multislice CT and cardiac scanning.
Henk has been Senior Product Manager CT since 2009.

"Aquilion ONE GENESIS Edition shows that our development has momentum – it's an ongoing process," said Henk Zomer. "It includes solutions for challenges that our users found in the Aquilion ONE. In fact, we not only found solutions, but made developments that give even higher than expected outcomes. In addition, the new system has groundbreaking new features. For example, laser collimation, through which we bring back the simplicity of X-Ray into CT. Basically, making a CT image, as you would make an X-Ray image, with all the advantages of a CT image at the same speed, and at the same ease of conventional X-Ray. That's a huge step in workflow and clinical confidence. We also focused on even further reduction of dose and refinement of image quality. To achieve this, we developed a completely unique, new model-based iterative reconstruction algorithm, called FIRST."

"With its groundbreaking new technologies, like FIRST, the Aquilion GENESIS developed over time, into a product that features image quality, reconstruction speeds and clinical applications that are yet unmatched by any other Area Detector CT. It's more user-friendly and with the latest software, many applications are 'zero click', improving workflow considerably," said Henk de Vries.

"CT systems generally have a lifecycle of about 10 years. When the early adapters bought the Aquilion ONE, they often had to adapt their buildings to fit the new system in." added Henk Zomer. "At that time, the 64-slice CT scanner dominated the market and the new GENESIS is a compact machine, that now can simply be installed installed in a 64--slice scanner room.The GENESIS was specifically designed with this in mind."

MODALITY OF THE FUTURE

There has been a significant increase in the number of diagnostic examinations carried out by CT in recent years. Industry changing innovations, like the introduction of the Area Detector CT and other subsequent developments, contribute to advancing this modality further.

"Although in the future, further dose reduction will continue to be important, the values are already so low now that the amount of contrast used in contrast enhanced scanning is becoming as important as exposure dose," explained Henk de Vries. "Shorter scan times, for which the Aquilion ONE is a perfect system, combined with optimized scan protocols already contribute to lower contrast amount. Next to this, we are developing new software to even further reduce the amount of iodine contrast needed."

"Use of CT scanning will continue to grow, because CT is easy to work with. Systems get faster and faster, and the dose gets lower and lower," said Henk Zomer. "With an ongoing commitment to CT development, Toshiba Medical's engineers are already working hard on the next generation of CT scanners."

A Decade of Developments in Area Detector CT

2000 – First Aquilion ONE prototype was ready.

2007 – Clinical and commercial introduction of Aquilion ONE signifying the birth of Area Detector CT and the first opportunity for physicians to scan organs in one rotation and view them in 3D and dynamic volume.

2012 - Introduction of the Aquilion ONE ViSION Edition enabling faster acquisitions and lower doses. Introduction of Iterative reconstruction techniques and the PUREViSION Detector that could deliver 4D dynamic capabilities at high resolution, with dose levels close to those used in routine diagnostic studies.

2016 - Introduction of the Aquilion ONE GENESIS Edition, which provides the user with techniques similar to conventional X-Ray. A smaller, faster system that is equipped with the latest PUREViSION Optics for improved image quality and lower dose.

"We were already the reference center for complex orthopedic cases. This CT-scan reinforces this situation and strengthen our image."

Prof. A. Blum

Head of the Radiology Department
Centre University Hospital Nancy, France

As an early adopter prof. Blum and his team have always been in the forefront of developments, in particular for MSK applications. The use of Area Detector CT has proven its benefits in a wide variety of orthopedic patients, prof. Blum has been a pioneer in 4D acquisitions and is hosting a dedicated CT MSK workshop together with his colleagues in Nancy, France.

1 What where your expectations at the time of installation of the Area Detector CT?

We were expecting a robust CT-scanner with innovative applications.

2 How did you experience the introduction of the Aquilion ONE in your hospital?

It was an amazing experience far beyond my expectations.

3 How has the installation of the Aquilion ONE changed your daily clinical practice?

New applications + new indications = more (interesting) work.

4 4D Imaging has changed patient pathways from the start, how did you start using them in clinical routine?

Empirical approach + serendipity = surprising and educative findings.
We use a progressive introduction of the technique in routine practice.

5 Quantification of movement is key when it comes to 4D acquisitions, what progression have you seen concerning this topic?

This is of course mandatory. We do need an objective way to assess and quantify normal and abnormal motion.

6 What has been the influence of the Aquilion ONE and Area Detector CT in patient management in your clinic?

We were already the reference center for complex orthopedic cases. This CT-scan reinforces this situation and strengthen our imaging capabilities.

7 Understanding the relation between motion and artifacts as well as adapting the acquisition protocol to the motion being evaluated is important, how do you standardize movement and optimize your protocols?

The SUREMove method that was developed in our department is very useful.

8 As Toshiba Medical CT's have seen some groundbreaking new techniques such as SURESubtraction and SEMAR, how do you experience these improvements and its clinical use?

That is an old story for our department as we have been using them for quite a long time now.
However, I have just found that combining these two techniques together creates a killer application of CT-scan for the detection of bone sarcoma recurrences after limb salving surgery.

9 With the introduction of AIDR 3D and FIRST, doses have been lower than ever before while Image Quality has improved. How has this influenced your clinical practice?

We are still in the process to understand the best parameters to use First with efficiency but this technique is obviously very promising.

10 Thinking out loud; what is your vision when it comes to the future of CT for the coming years?

- Better spatial resolution along with better contrast to noise ratio
- Ultrafast reconstruction time
- High speed transfer to the PACS
- Functional imaging for interventional radiology.

CTEU160120 ©2017 TOSHIBA MEDICAL

CTEU150099

DOWNLOAD THE FULL ARTICLE ON:
www.toshiba-medical.eu/eu/ct-campaign-10-years-ahead

Clinical Experience with 4D Ortho Application

Dynamic CT Post Processing of the Musculoskeletal System

Teixeira Gondim, Pedro Augusto MD, PhD. Blum, Alain MD, PhD

Motion is frequently involved in the pathogenesis of musculoskeletal diseases. With static imaging methods, the diagnosis of dynamic pathology (e.g. friction and impingement syndromes) is based on secondary findings only[1]. This fact and the frequency of these conditions underscore the importance of dynamic imaging modalities in the evaluation of musculoskeletal diseases. Wide area-detector CT is suited to dynamic study of joints, allowing volumetric study of bone and intra-articular ligaments during physiologic motion or under stress maneuvers. Dynamic CT is complementary to other dynamic methods, helping overcome some of their limitations, such as evaluation of bony and intra-articular structures with ultrasound or superimposition of structures on fluoroscopy[2]. Dynamic CT is most frequently used for the evaluation of the wrist, but can be used on various joints (shoulder, hip, elbow, knee, and ankle)[3-5].

CLINICAL EXPERIENCE

Since 2008, dynamic CT has been performed in our institution for the evaluation of musculoskeletal diseases. Wrist and ankle dynamic CT studies performed routinely were post-processed using the 4D-Ortho application. A total of ten studies were included in this analysis.

All studies were performed with a 320 detector-row CT scanner (Aquilion ONE, Toshiba Medical Systems, Otawara, Japan). Bone locking was possible in all cases and improved motion visual analysis markedly, by reducing the influence of through-plane motion. In our opinion, the use of a static reference for motion analysis allows a better appreciation of the amplitude of the target motion and improves the analysis of each individual moving bone.

Discussion and Conclusion: 4D-Ortho was successfully used in the evaluation of clinical data, offering reproducible, semi-automatic measurements of distances and angles. Musculoskeletal dynamic CT is a relatively new technique and its clinical application is just beginning. Quantitative analysis is of great importance for the dissemination of this technique, since it facilitates the establishment of general diagnostic criteria that currently remain absent in literature. Clinical studies are currently being performed with the aid of 4D-ortho application in normal and pathologic patients, to assess normal and pathologic variation of distances and angles during different types of motion and in different joints.

In conclusion, 4D-Ortho represents a major development in the post processing of musculoskeletal dynamic CT. This application has the potential to improve diagnostic performance and reproducibility of musculoskeletal dynamic CT, playing an important role in the clinical application of this technique.

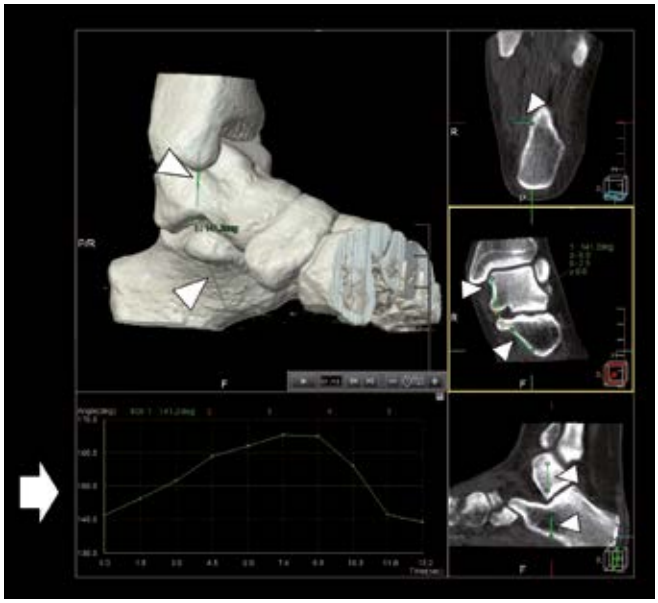

1. Guillin R, Marchand AJ, Roux A, Niederberger E, Duvauferrier R. Imaging of snapping phenomena. Br J Radiol. 2012 Oct;85(1018):1343–53.
2. Gondim Teixeira PA, Gervaise A, Louis M, Lecocq S, Raymond A, Aptel S. Musculoskeletal Wide detector CT: Principles, Techniques and Applications in Clinical Practice and Research. European Journal of Radiology. 2015 (in press);
3. Wassilew GI, Janz V, Heller MO, Tohtz S, Rogalla P, Hein P, et al. Real time visualization of femoroacetabular impingement and subluxation using 320-slice computed tomography. J Orthop Res. 2013 Feb;31(2):275–81.
4. Totterman S, Tamez-Pena J, Kwok E, Strang J, Smith J, Rubens D, et al. 3D visual presentation of shoulder joint motion. Stud Health Technol Inform. 1998;50:27–33.
5. Edirisinghe Y, Troupis JM, Patel M, Smith J, Crossett M. Dynamic motion analysis of dart throwers motion visualized through computerized tomography and calculation of the axis of rotation. J Hand Surg Eur Vol. 2014 May;39(4):364–72.

Professor Albert de Roos,
Professor of Radiology at the LUMC

©2017 TOSHIBA MEDICAL

Equipped to take on any challenge

Leiden University Medical Center (LUMC) in Leiden, the Netherlands, is focused on high quality research, education and patient care with a strong scientific orientation. It was one of the very first hospitals in Europe to welcome an Aquilion ONE™ CT system. Professor Albert de Roos, Professor of Radiology at the LUMC explained how the scanner and partnership with Toshiba Medical has opened many doors, not only to new techniques and clinical possibilities, but also to important collaborations with other research experts across the world.

In 2000, LUMC decided to broaden its investment in new CT technology. Its partnership with Toshiba Medical began then.

"We were surprised and happy to see how Toshiba Medical was connecting within Europe at that time," said Professor de Roos. "They were serious about collaborating with the LUMC and were very motivated. We were able to establish a very personal relationship early on, which has worked well throughout the years and continues until today. We particularly appreciated the consistently friendly and helpful attitude and strong commitment of the Japanese- and European Toshiba Medical management and staff. Factors that form the basis of this excellent collaboration – The good 'marriage' between Leiden and Toshiba Medical. We have many relationships within our industry, but sometimes these lack depth and meaning, this, however, is something completely different."

"Due to this good relationship, we were always informed about new developments in advance," he continued. "That's quite unusual in the industry. It meant we could always be prepared if something new was on the horizon. Toshiba Medical was also keen for us to receive the new equipment as early as possible. That was exciting and stimulating and gave us a good feeling and confidence that we were in the lead of new developments. We were able to connect LUMC's Radiology Department and our Physics Group with Toshiba Medical's Engineers in Japan: an excellent interaction, well-prepared, with a smooth introduction. Toshiba Medical is also always great steps ahead with new systems and technologies."

EVOLUTION AND REVOLUTION

LUMC first acquired a Toshiba Medical 4-slice CT scanner in 2000, moving to 16-slice in (2003), 64-slice in (2005), and the Aquilion ONE in the beginning of 2008. With each new CT generation, LUMC's Radiology Department looked forward to the new possibilities that each successive system would bring for them and their patients.

"Every step was a major breakthrough and provided so many new opportunities. We were always surprised by the options provided with every new generation. Toshiba Medical's commitment to long-term CT development makes a lot of difference and is recognizable in its products, which are always at the forefront of new technology," remarked Professor de Roos. "There was a particularly big transition from 64-slice to Aquilion ONE. The volume scanning offered by the Aquilion ONE was truly new in the field of CT. It was a surprising leap forward to be able to scan a whole volume in one rotation. Volume CT, which remains quite unique to Toshiba Medical, has some remarkable applications.

The introduction of each new system at the LUMC was successful, and the installation of the Aquilion ONE was no exception.

"The introduction of the Aquilion ONE, with its new possibilities to collect functional, as well as morphological data into clinical practice, went smoothly, and it worked!" exclaimed Professor de Roos. "We didn't need to start from scratch, and we could develop some entirely new applications and protocols within a short space of time, because the CT was always working properly. We are still finding new ways to build on them. There is always the challenge to do more and better, but this is how new routine applications have emerged, for example, in cardiac scanning. The combination of Aquilion ONE's volume CT and the fast acquisition is a real advantage."

VOLUME SCANNING BREAKTHROUGH

Volume scanning with the Aquilion ONE enabled coronary imaging in cardiac applications. It is now a routine tool at LUMC and is even used in pediatric applications and congenital heart disease patients.

"Recent trials have shown that coronary CTA can replace coronary angiography[1]," said Professor de Roos. "In the early days, cardiologists laughed at the concept of cardiac CT. They compared radiologists with Monty Python and

Professor de Roos is internationally renowned for his expertise in research into cardiac imaging and Magnetic Resonance imaging. Alongside key roles in the Radiology Departments of the LUMC in the Netherlands, and the University of Pennsylvania, Philadelphia, in the US, he has authored or co-authored more than 400 scientific articles and is a Deputy Editor of the scientific journal, Radiology.

the Holy Grail! They envisaged us wandering through the desert, searching for a tool to image the coronary arteries, and they laughed and said: "These radiologists are crazy: it will never happen, every option has already been tried over many years!"…. Nowadays, it's standard. That shows how these things evolve. There's always the same pattern that happens in development. Many leading professors are skeptical of new technology at first. You need to have great vision and accept the challenge to develop these techniques to a higher level. It's then a pattern of acceptance by early adapters and then the wider audience."

OPENING DOORS TO MULTICENTER STUDIES

With the Aquilion ONE, LUMC were able to join multicenter trials – international research collaborations between institutes located across the world.

"Toshiba Medical showed great foresight in starting scientific research initiatives alongside to commercial activities to evaluate and promote new CT technologies," he said. LUMC was able to work on multicenter trials between Europe, Japan and the US, and that started a significant collaboration: the so-called 'CORE-64 Project[2]'; and later the 'CORE-320 Project[3]'. The projects were very successful and the results were published widely. Toshiba Medical unusually and successfully combines European, Japanese and American standards. The projects also created a sort of 'Toshiba Family' between the Aquilion ONE users in different global locations."

SETTING NEW STANDARDS IN DOSE REDUCTION

At the time of introduction of the Aquilion ONE, a major focus was on dose reduction in the CT industry. Dose reduction is very important for general health issues, for imaging wisely, particularly for example in using low doses for imaging children.

"Toshiba Medical has been in the forefront of dose reduction techniques, but I think the issue is now becoming less and less relevant, because low-dose has become standard," added Professor de Roos. "With doses becoming so low, I believe that standard radiography applications will be taken by CT in the future. For example, routine chest films and other applications will maybe increasingly be performed as low-dose CT applications. I think that CT technologies also provide new opportunities for new ways of image analysis. So that a computer with a self-learning algorithm will actually go through the data sets by CT and pick out the abnormalities. Maybe we can achieve this with automated techniques more efficiently than with the eye of a physician? I think this might fit with the CT modality especially well. We will see how these things develop.

NEXT STEPS IN CARDIAC CTA

Professor de Roos shares Toshiba Medical's commitment to continual progress.

"It never stops. At every step, people always think that: "This is the top of the hill!"…but after every hill, there is a new hill," he concluded. "There will certainly be other new applications and possibly new detectors introduced, such as Photon Counting detectors. Perhaps, people will integrate CT technology with other modalities, because CT currently has some limitations. Maybe we will see CT and MR or some other modality combined to leverage the strengths of each. People always want to have one modality that fits all, but mostly that carries some limitations. Will have to wait and see how these things might improve…So onwards and upwards to the next hill!

References:

1 Evaluation of Computed Tomography in patients with atypical angina or chest pain clinically referred for invasive coronary angiography: randomised controlled trial. Marc Dewey et al. BMJ 2016;355:i5441.

2 Radiation Exposure to Patients in a Multicenter Coronary Angiography Trial (CORE 64).Jacob Geleijns, Raoul M. S. Joemai, Marc Dewey, Albert de Roos, Maria Zankl, Alfonso Calzado Cantera and Marçal Salvadó Artells. American Journal of Roentgenology. 2011;196: 1126-1132. 10.2214/AJR.09.3983.

3 Computed Tomography angiography and perfusion to assess coronary artery stenosis causing perfusion defects by single photon emission Computed Tomography: the CORE320 study. Rochitte CE, George RT, Chen MY, Arbab-Zadeh A, Dewey M, Miller JM, Niinuma H, Yoshioka K, Kitagawa K, Nakamori S, Laham R, Vavere AL, Cerci RJ, Mehra VC, Nomura C, Kofoed KF, Jinzaki M, Kuribayashi S, de Roos A, Laule M, Tan SY, Hoe J, Paul N, Rybicki FJ, Brinker JA, Arai AE, Cox C, Clouse ME, Di Carli MF, Lima JA. Eur Heart J. 2014 May;35(17):1120-30. doi: 10.1093/eurheartj/eht488.

©2017 TOSHIBA MEDICAL


Das gute Herz des HSV
BILD mit dem Trainer beim Medizin-Check
Toshiba presents the Aquilion
first dynamic volume Computed
scanner with 320 simultaneous slices
Ein einziger
Herzschlag ge
Installation of Aquilion ONE™
SPECIAL COMPUTED TOMOGRAPHY
T: Optimising
the 320-slice CT scanner
briše ožiljke
Dynamisch
Schau mir in die Adern
NEUE GERÄTE VERRINGERN STRAHLENDOSIS UM 80 PROZENT
COMPUTERTOMOGRAF

"We are constantly looking to improve, always with respect to image quality, radiation dose and contrast volumes."

Matthew Benbow
Lead radiographer CT
Royal Bournemouth Hospital,
Bournemouth, UK

Dr. Russell Bull
Consultant Radiologist
Royal Bournemouth Hospital,
Bournemouth, UK

Close collaboration between radiographers and radiologists is key to optimize protocols and reduce the use of iodinated contrast media. The Royal Bournemouth Hospital uses the Area Detector technique to its fullest; from iodine reduction in Cardiac scans to scanning CTPA studies without breath hold.

1 How did you experience the introduction of the Aquilion ONE in your hospital?

This was a very exciting time. After spending many years performing helical scans, I was really keen to see volume scanning in action and to explore what applications we could convert to this method.

2 As training and education are a key aspect in your clinical environment; how did you handle training at your department when starting to use the Aquilion ONE?

The local applications specialists were really knowledgeable and spent time with us to ensure we were able to create all the scanning protocols we required. As several of these were to become wide area protocols we organized some local teaching sessions in our seminar room. It soon became apparent however that cardiac CT with wide area detector CT is actually more straightforward than retrospective helical protocols and so it was possible to get all 23 radiographers up to speed within a reasonable amount of time.

3 In day to day use, what advantages does Area Detector CT add to your clinical environment?

All coronary artery CT converted immediately to single rotation, area detector CT. As a consequence radiation doses dropped to a fraction of what we had been used to. We immediately ceased performing a calcium score preliminary scan as the dose for the main angiogram is the same. We were also able to reduce contrast volumes greatly as the scans were completed so rapidly.
In addition there was a huge increase in robustness and we were able to scan patients with arrhythmias or poor breath-hold capabilities for the first time.

In addition to cardiac applications, wide-area detector CT is also incredibly useful in patients who are unable to keep still for a conventional examination. As the entire organ of interest is covered in a single rotation we are able to obtain brain images in restless patients and CTPA studies in severely dyspneic patients without the need for breath-holding

4 How do you optimize and adjust protocols in your hospital?

We regularly discuss protocols to ensure we are putting constant thought into what we are doing. We get regular updates of techniques and protocols being performed elsewhere through the applications specialist team, and we incorporate those that suit our service. We are constantly looking to improve, always with respect to image quality, radiation dose and contrast volumes. A good example has been the change to 100 kVp for all routine scanning as a first line kVp. The added contrast enhancement offered has allowed us to significantly reduce the contrast volumes we give our patients.

©2017 TOSHIBA MEDICAL

5 How did you experience the evolution of Aquilion ONE in the last 10 years? From both software as well as hardware point of view?

Reliability of our Aquilion scanners has always been superb, and this has persisted as changes have been made. Tube outputs were improved with the Aquilion ONE™ ViSION Edition, such that high mA scanning has been possible routinely. This, in conjuction with greatly improved detector efficiency has enabled lower kVps to be used, improving the effect of IV contrast and allowing us to reduce the dose. Rotation times have shortened and as such this improves the temporal resolution achievable for all studies, but particularly for coronary artery CT. Radiation doses for coronary CT are now so low that we are able to use this technology even in very young patients. Other options such as lateral table movement, ultrahelical scan mode and variable helical pitch have all allowed more challenging examinations to be achieved with good image quality. Iterative reconstruction (AIDR 3D) has reduced doses whilst maintaining image quality and metal artifact reduction (SEMAR) has become available in both volume and helical modes which not only massively improves orthopedic studies, but the soft tissues around implants, such as enabling good visualization of the bladder when hip prosteheses are present.

6 Thinking out loud; what is your vision when it comes to the future of CT for the coming years?

Firstly, wide area CT has to be the single biggest benefit that all scanners should aspire to. Whilst much of our general work is performed in helical mode , and always will be, for specialist examinations such as cardiac CT, the benefits of a wide, ultra-efficient detector in terms of image quality and patient dose are considerable and our vision would be that all large volume cardiac centres will use this type of technology in the future. Further improvements in detector technology, reconstruction systems and high output tubes will reduce radiation doses still further, allowing lower kVps to become the norm. With this comes the benefit of really being able to utilise extremely low volumes of contrast media and as such I believe that syringe injectors will become inappropriate for use, and continuous delivery systems will become exclusively purchased.

I would predict that within the next 10 years there will be major advances in the spatial resolution of CT due to a combination of ultra-high-resolution detectors and advanced model based iterative reconstruction. This will allow CT to equal or even surpass the resolution of catheter angiography. This, in combination with functional assessment of lesion severity based on advanced fluid dynamic modelling will allow CT to become the standard diagnostic test for all cases of suspected coronary artery disease thus allowing cardiac cath labs to concentrate exclusively on interventional procedures.

For non-coronary applications, CT doses will be down to such low levels that there will be very little justification for performing conventional plain films for many indications. My prediction is that in 10 years time an average mid-sized general hospital will have perhaps 2 plain film rooms and 8 ultra-low dose CT scanners. The challenge for the imaging departments of the future will be to report all these studies in a timely manner and we are likely to need help from advanced visualisation and processing techniques in conjunction with computer-aided diagnosis.

CTEU150108

DOWNLOAD THE FULL ARTICLE ON:
www.toshiba-medical.eu/eu/ct-campaign-10-years-ahead

CLINICAL CASE ABSTRACT

CTPA, Lungs, Subtraction

Lung SURESubtraction in Everyday Practice

Dr R. Bull, Royal Bournemouth Hospital, UK

Post contrast iodine maps were introduced as part of dual-energy imaging over 10 years ago but these have never become part of routine practice in most centers for the investigation of pulmonary thromboembolic disease. As dual energy imaging utilizes the post contrast difference in attenuation of iodine between 2 separate kVp images, the amount of signal generated is rather small meaning that noise levels have to be low in order to generate images with sufficient signal to noise ratio.

SURESUBTRACTION – IODINE MAPS WITHOUT THE RADIATION PENALTY

This is a novel technique whereby signal generated from a pre contrast image (typically at 100 kVp) is subtracted from the same anatomical area scanned post contrast. It results in much higher signal generation compared with dual energy. This allows radiation doses to be reduced to very low levels on both pre and post contrast scans whilst maintaining a high signal to noise ratio. In combination with the ultra-dose efficient PUREViSION detector this allows iodine maps to be used routinely in the investigation of thromboembolic disease at extremely low radiation doses. Although conceptually simple, the key to the success of SURESubtraction is advanced non-rigid registration allowing compensation for slight patient movement or differences in breathing between the pre and post contrast scans. SURESubtraction also has the advantage that there is no restriction on field of view, allowing iodine maps to be obtained even in large patients (dual tube systems are restricted due to the limited field of view of the 'B' tube).

SURESUBTRACTION ALLOWS DETECTION OF SUBTLE LUNG DISEASE

Conditions such as small airways disease cause air trapping and reduced lung attenuation. Although this can be very significant functionally, this is easy to miss on conventional anatomical images as the difference in lung attenuation can be small (Fig. 5a). As air trapping leads to hypoxic pulmonary vasoconstriction, changes in blood flow and thus iodine concentration are much more obvious (Fig. 5b).

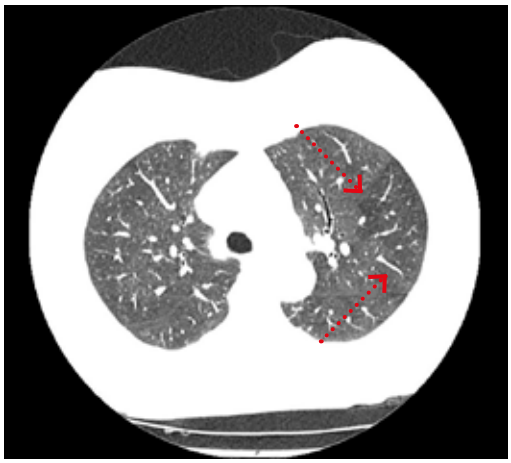

Figure 5a: Subtle geographical area of reduced attenuation in left upper lobe indicating small airways disease (arrows).

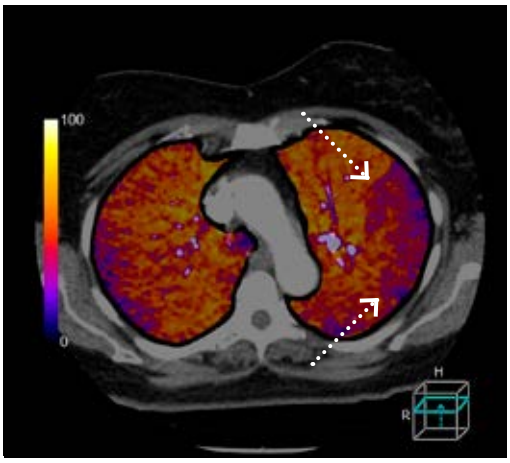

Figure 5b: corresponding iodine map demonstrating obvious wedge shaped defect in same area due to reduced blood flow (arrows).

[1] *Royal Bournemouth Hospital, UK*

©2017 TOSHIBA MEDICAL

Please visit:
www.toshiba-medical.eu/eu/education
for more information.

2007 2008 2009 2010 2011 2012

2007
Introduction Aquilion ONE

2009
Introduction of software such as vHP, Wide Volume Scan Mode, PhaseXact

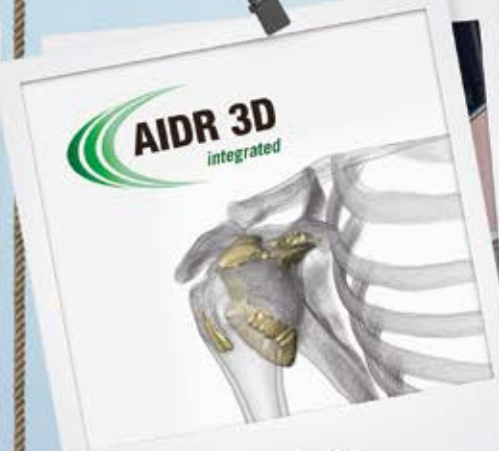

2011
Introduction of AIDR 3D

2008
First Aquilion ONE installation Europe, introduction of volumetric scanning

2010
Introduction of 100 and 160 row Ultra Helical Scan Mode

2012
Introduction of Aquilion ViSION Edition

©2017 TOSHIBA MEDICAL

2 2013 2014 2015 2016 2017

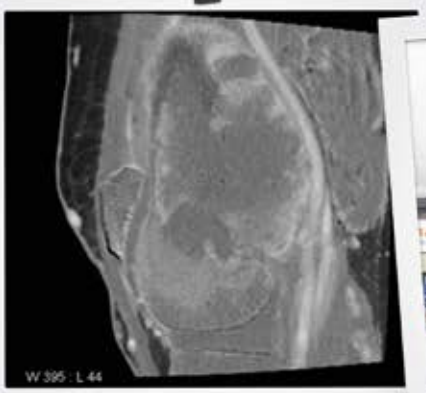

2013
Introduction of Toshiba unique SURE Subtraction Techniques

2015
Introduction of PUREVISION Detector, introduction of FIRST

2017
Aquilion ONE GENESIS Edition

ONE

Adaptive Diagnostics
Clinical Solutions

2014
Introduction of Adaptive Diagnostics

2016
Introduction of Aquilion ONE GENESIS Edition

The Future...

"The introduction of our first Aquilion ONE opened a whole new world, scanning got much more advanced and challenging with a whole new range of possibilities."

Willem-Jan van der Woude

Lead radiographer CT
Radboud University Medical Center, Nijmegen, The Netherlands

As a CT lead radiographer in Nijmegen Willem-Jan has extensive experience using Toshiba Medical's Area Detector CT's in all sort of environments; from trauma to pediatric patients. With Nijmegen as an early adapter of CT technique Willem-Jan experienced a number of product introductions and the introduction of a large number of software applications. Keeping up with this pace can be a challenge but it is a challenge Willem-Jan and his colleagues have always lived up to.

1 How did you experience the introduction of the Aquilion ONE in your hospital?

After years of using some older CT scanners the introduction of our first Aquilion ONE™ opened a whole new world, scanning got much more advanced and challenging with a whole new range of possibilities.

2 As training and education are a key aspect in your clinical environment, how did you handle training at your department when starting to use the Aquilion ONE?

We started to train five key-users at Toshiba Medical, these key-users were responsible for training their colleagues. During the first week application was on site for training and improving protocols towards hospital standards.

3 In day to day use, what advantages does the Aquilion ONE and Area Detector CT add to your clinical environment?

With an Aquilion ONE on the Emergency Department brain perfusion, with coverage of the complete brain, is now our standard care in patients with CVA. Cardiac scanning is made easy with a average patient dose of 1-2mSv in one single heartbeat.

4 How do you optimise and adjust protocols in your hospital?

Protocols are being reviewed on a regular base in a group existing of radiologists, radiographers and physicians. During this meetings suggestions for optimizing and evaluation of changes are made.

5 How did you experience the evolution of Aquilion ONE to GENESIS? From both software as well as hardware point of view?

Our Aquilion GENESIS came with the same software version as the Vision so no changes there. On the hardware point of view there were some great changes. The CT is equipped with a view finder and start button on the gantry, this can be used for scanning extremities and little children. There's also more filtering of the beam, resulting in a more homogene X-ray beam. Therefore scanning at 80kV is quicker available in Cardiac scanning which gives the opportunity for further reducing the amount of contrast.

6 Thinking out loud; what is your vision when it comes to the future of CT for the coming years?

The biggest developments in CT will rather be made on the software side then on the hardware side. Techniques like iodine mapping and subtraction will hopefully be available soon for al scans where multiphase scan are applied.

CTEU160123

©2017 TOSHIBA MEDICAL

10 YEARS ADVERTISING

Prof. Dr. Bernd Hamm
Director of the Institute of Radiology

Anniversary Interview with Professor Bernd Hamm, Director of the Institute of Radiology (Middle Campus), Clinic for Radiation Therapy (Virchow Clinic Campus), Clinic and University Outpatient Department for Radiology (Benjamin Franklin Campus) at the Charité Hospital, Berlin, Germany.

10 Years Ahead

The Radiology Clinic of the Charité Hospital in Berlin, Germany, is one of the largest of its kind in Europe. In 2016, 473,023 radiology cases were handled there for a total of 147,324 patients in the capital city, distributed across three campuses. There were 60,721 CT scans alone. The clinic set a prominent example 10 years ago: In 2007, the first Aquilion ONE™ CT system in Europe was installed at the Hospital. The Director of the three clinics, Professor Bernd Hamm, takes stock.

What were your expectations when the Aquilion ONE was installed?

Our expectations of the new device were high. As we had already enjoyed a good collaboration with Toshiba Medical for more than 10 years and had found the company to be innovative and above all very reliable in the CT area, we had justified hopes that we would be able to reach the next level of CT diagnostics with the Aquilion ONE. Seven out of 12 CT devices at the Charité Hospital are Toshiba Medical devices (plus two other devices used for radiation therapy and forensic medicine).

How did the introduction of the Aquilion ONE go at your hospital?

Introduction of the Aquilion ONE was very smooth. Thanks to the predecessor models, the Medical Technical Radiology Assistants (MTRAs) and physicians were already familiar with the Toshiba Medical interface. And, as I said, we already had a close, cooperative relationship with Toshiba Medical.

©2017 TOSHIBA MEDICAL

Why was the Aquilion ONE selected?

Other than the fact that the CT was advertised throughout Europe, there was a functional and emotional reason for this. At the functional level, the convincing aspect was that the Aquilion ONE allows you to collect a combination of morphological and functional data, which was not possible before. These data include those for cerebral perfusion, myocardial function, and myocardial perfusion, as well as cardiac valve function, to some extent. In the meantime, we've introduced pancreatic perfusion in low-dose technology. Today, the Aquilion ONE is being used in all areas, including for full organ- and tumor perfusion.

What was the emotional reason?

The emotional aspect was equally important. We had amassed very good experiences with Toshiba Medical over the years. We were ready to take the next step together with the use and evaluation of the Aquilion ONE. There was no reason to change manufacturers.

How did installing the Aquilion ONE change clinical practice?

Installation of the device clearly expanded the range of indications. Or to put it in other words: with the Aquilion ONE there are fewer contraindications. The CT enables diagnostics to be performed on a much larger patient population. For example, in the past, patients with arrhythmias were hardly ever considered for CT diagnostics. Due to the arrhythmias, the diagnostic informative value of the images was greatly reduced. Today, such examinations are stable and provide much better diagnostic information, thanks to 'Single Beat Cardio Imaging'. We even achieve good results with the Aquilion ONE for obese patients. We can increase the tube current – thereby, accepting a higher dose. The diagnostic information is persuasive and trend-setting for future therapy.

In what areas did the Aquilion ONE bring about new developments?

Dual-energy technology in diagnosing gout is one new indication, for example. With this technology, two images are taken of the joint with two different X-Ray radiation energies. Comparing these images allows you to see if a deposit is made of calcium- or urate crystals. Dual-energy technology makes it easier to demarcate inflammatory- or degenerative changes of gout-specific deposits. There are also major advances in stroke diagnostics. Volume CT makes it possible to take 3D perfusion images of the entire brain. The decision as to whether the patient is eligible for intravascular therapy or not can be made much faster.

When the Aquilion ONE was introduced, there was a large 'dose discussion' going on in the CT arena. How did you tackle the issue of optimizing protocols in your clinical routine?

Actually, there was an intense dose competition going on at that time. The Aquilion ONE had the advantage of allowing flexible optimization of protocols. For example, certain problems can be assessed with a low dose and image noise. The examiner minimizes the dose with a dedicated design of the examination protocol. The algorithm of the adaptive iterative dose reduction also results in a significant dose reduction. The Aquilion ONE is an excellent tool for reducing the radiation dose.

What impact have the Aquilion ONE and flat-panel detector CT (with a 16 cm detector) had on patient management?

The frequency with which patients are examined has not increased significantly due to the introduction of the Aquilion ONE. That's because we already had Multislice CTs and a high throughput before. Furthermore, the actual CT exam is not the limiting factor at a maximum-care facility. Instead, the limiting factor is much more the placement and positioning of bed-ridden and intensive-care patients. The Aquilion ONE makes it possible to achieve good diagnostic results with stable quality for a larger patient population.

Which hardware and/or software advances have you witnessed since 2007?

It may sound like a small thing, but the rotation time reduction from 350 milliseconds to 275 milliseconds really pays off. We now have significantly improved image quality in cardiac diagnostics in particular. The AIDR 3D software has also proven itself in terms of iterative image reconstruction. The variable tube output is also an advantage, because we can increase it for obese patients. And vice versa, we can better use the contrast effect in the low kilowatt range – and we can decrease the amount of contrast medium for patients with renal failure.

How would you describe the relationship between Charité and Toshiba Medical?

Allow me to give you a brief retrospective on that: I admit that I was skeptical when the decision was first made to install a Toshiba Medical device. We didn't know the company very well. We weren't sure whether a development department in 'far-away' Japan would be to our advantage. However, over the years, the reliability of Toshiba Medical's employees has been exemplary. I personally value the fact that a promise is an absolute promise in

Japanese culture. Scheduled updates, for example, have always been installed by the agreed-upon date at the latest. And Toshiba Medical's employees continue to impress me. They are technically oriented and less interested in marketing. They are Medical Engineers, not Sales people.

Which recent improvements are important to you?

The development of increasingly customized imaging is an advantage. This includes saving on contrast medium, thanks to low tube output, depending upon the individual situation. Or reducing the radiation exposure thanks to the iterative reconstruction and customized exam protocol design. A reduced dose and a decreased contrast medium amount have become a reality. Measuring the intra-arterial blood flow and the myocardial perfusion are future technical advances that are currently still in the clinical investigation stage.

Which trends are you currently seeing in Radiology?

The current trends are Big Data and Artificial Intelligence. It's very exciting. Of course, innovations also have the power to frighten people, but there's no reason for this. As even though Artificial Intelligence will certainly make its way into the Radiology field, it will remain an aid, as opposed to becoming competition. You can draw a comparison with civil aviation: the autopilot feature is highly valued. But no one would take a flight if the plane were being piloted only by the autopilot without an actual cockpit crew. Artificial Intelligence will enrich radiology but won't replace the competence of Radiologists.

What does the future of CT look like in your opinion?

CT could develop in parallel with the self-driving car in the future. The CT 'accelerates, brakes and parks', just like a self-driving car. Depending on the medical question and the patient data, CT will optimize the examination protocol in all relevant aspects.

Once the device has calculated the best possible result from all the data, it will give the Radiologist a recommendation for an optimized individual protocol. There will be fewer standardized examination protocols the way these are usual and justified today. Software programs that flexibly align the examination protocol with the individual case in the future would further increase the quality of the radiological findings.

©2017 TOSHIBA MEDICAL

"The 16 cm detector allowing whole head imaging in one rotation has allowed us to develop better venous phase imaging for CTV with added advantage of lower contrast dose."

Dr. K. Das
Consultant Neuroradiologist

Yvonne Shanks
Radiology Manager

The Walton Centre is the only NHS Trust in the UK dedicated to Neuroscience. The group at the Walton Centre has published in renowned journals such as the AJR and they use their Area Detector CT to the fullest in the challenging patients they see in daily clinical practice. Please find below their view on the role of Area Detector CT in Neuroradiology.

1 What where your expectations at the time of installation of Aquilion ONE?

Our expectation were high with the hope of doing better and more complex imaging. We knew upgrading from a 4 slice to a 320 slice scanner would be a learning curve.

2 How did you experience the introduction of the Aquilion ONE in your hospital?

The installation was very well managed with minimal disruption to clinical services.

3 How has the installation of the Aquilion ONE changed your daily clinical practice?

CT has become a more versatile tool and as a result usage has increased.

4 What has been the influence of the Aquilion ONE and Area Detector CT in patient management?

The main influence has been in better neurovascular imaging.

5 In a recent publication The Walton Centre presented two cases where an intranidal aneurysm was demonstrated on four-dimensional CT angiography (4D-CTA). Where do you see 4D-CTA in the detection and management of AVM's?

4D-CTA is likely to have a significant impact on charcterisation of AVM with the aim of using 4D-CTA to replace diagnostic catheter angiography in relevant cases. We have also worked to significantly reduce doses in 4D-CTA as published recently in American Journal of Neuroradiology.

6 In the American Journal of Roentgenology The Walton Centre has published an article describing a method for Cerebral CTV scanning using a low volume of contrast agent, how has the Area Detector Technique supported the use of this method and the reduction of contrast agent used?

We have utilized the faster scanning techniques to develop new CT Venography technique. The 16 cm detector allowing whole head imaging in one rotation has allowed us to develop better venous phase imaging for CTV with added advantage of lower contrast dose. We also published a similar technique for CT Angiography in Clinical Radiology Journal – again with better arterial phase with reduced contrast dose.

7 Combined CTA/CTP data can provide visualization of dynamic flow and perfusion. Area Detector CT allows for whole-brain perfusion, what role do you see for whole brain perfusion other than in stroke imaging?

We have used whole brain perfusion in determining cerebrovascular reserve in patients with haemodynamic transient ischaemic attacks to help determine selection for arterial bypass. We have also used it to assess vasospasm in post- aneurysm coiling patients.

8 How has the introduction of Single Energy Metal Artifact Reduction (SEMAR) impacted diagnostic image quality to your opinion?

It has had provided much quality imaging in both patients with aneusym clips and spinal instrumentation.

9 Thinking out loud; what is your vision when it comes to the future of CT for the coming years?

CT provides specific contrast detail not achievable by other imaging modality and I expect its use will continue to increase and diversify. With improvements in dose reduction, it may replace many of the of plain radiography techniques such as chest X-rays.

"We are able to scan many patients we wouldn't have attempted previously without anaesthesia."

The Bristol group

Bristol Royal Hospital for Children, Bristol, UK

The Bristol Royal Hospital for Children (BRHC) provides a local service for Bristol children and a referral service for specialist care for families across the South West and nationally. Currently they have 11 full time and 2 part time Paediatric Radiographers and 5 consultant Paediatric Radiologists including one Professor.

1 What where your expectations at the time of installation of Area Detector CT's?

Faster acquisition times, less table movement therefore less sedation and decreased risk of failed scans

2 How did you experience the introduction of the Aquilion ONE / ViSION Edition in your hospital?

Very smooth. The Applications training and support thereafter was second to none.

3 How has the installation of the Aquilion ONE / ViSION Edition changed your daily clinical practice?

We are able to scan many patients we wouldn't have attempted previously without anaesthesia.

4 How do you prepare your pediatric patients for a CT scan?

- Play Specialist Team
- Model scanner
- Breath hold practice using the iStation console
- Demonstration- ride on the table, press buttons to move table etc.

5 To what extent can CT replace or add information in the visualization of airway disease in pediatric patients?

4D Dynamic Airway CT- allows dynamic visualization of airway collapsibility without having to inject contrast into the bronchus. In addition the volumetric scanning precludes mis-registration of the location of any trachea-bronchomalacia and allows full cine viewing of dynamic airway collapse. By adding IV contrast we can see vascular information and its relationship to the airway.

6 What has been the influence of the Area Detector CT in patient management?

We have found reduced requirements for anaesthesia and less motion artifacts. Furthermore we have improved image quality in general at lower doses and improved cardiac imaging at lower doses. Due to the 4D Dynamic Airway CT we undertake less bronchograms examinations.

7 Limiting the amount of Iodinated contrast used in a scan is key to reducing the risks of a CT scan. An example is the split bolus technique you are using in Bristol. How do you use this technique in your clinic?

With faster acquisition times at 80-100kV we have reduced our body contrast dosing from 2mls/kg to 1.5mls/kg. For trauma patients we use a biphasic contrast protocol that means the patient is only scanned once for arterial and venous phases in one scan. Our modified camp bastion protocol uses a split bolus technique with a pause in between boluses. This has resulted in better biphasic contrast scans with less contrast than the camp bastion wheel method.

8 How do you handle the optimization of protocols and the optimization of dose in your department?

We have a very good working relationship with our applications specialist who has been instrumental in helping us tailor protocols to the requirements of our patients. We started out by setting a baseline of achieving doses within DRL and what we were achieving previously. Currently we are working towards optimizing paediatric chest protocols. Using sure exposure 3D we have been able to reduce dose incrementally by small increases in standard deviation without noticeable reduction in image quality.

9 How has the introduction of the Aquilion ONE opened doors to new ways of imaging in your department?

It is ideal in our current status as a Level 1 paediatric major trauma centre.

We offer a new solution for imaging tracheo-bronchomalacia for neonatal ICU patients and for children with complex cardiovascular abnormalities.

In our capacity as a tertiary referral centre for orthopaedic limb lengthening and correction surgery as well as spinal scoliosis surgery the SEMAR technology has greatly improved our imaging of patients with metallic hardware.

10 Thinking out loud; what is your vision when it comes to the future of CT for the coming years?

Considering the existing disfavour of CT for paediatric practice in the United Kingdom because of concerns regarding radiation doses, the Aquilion One™ is serving to demonstrate significant advantages of CT with regards to speed (reducing the requirement for anaesthesia), dynamic airway imaging and artefact reduction when imaging metallic hardware, with doses well within acceptable levels for paediatric imaging.

©2017 TOSHIBA MEDICAL


ONE
Aquilion
TOSHIBA

CTEU160114

DOWNLOAD THE FULL ARTICLE ON:
www.toshiba-medical.eu/eu/ct-campaign-10-years-ahead

CLINICAL CASE ABSTRACT

Dose, Metal artefact reduction

German Armed Forces and Patients Benefit from New Options for Low-Dose Volume CT

Dr. S. Waldeck[1]

The Radiologists at the Bundeswehr Central Hospital in Koblenz (BWZK), Germany, used the high-end volume CT - Toshiba's Aquilion ONE™ / ViSION Edition - for several months, along with the Vitrea Advanced web-based image-processing software. The new, low-dose volume CT expanded clinical diagnostics and provided added value for trauma- and routine CTs, as well as special examinations.

The Diagnostic and Interventional Radiology department comprises of a team of 19 doctors and 24 technicians who work under the direction of Head Doctor, Dr. Stephan Waldeck. The new Volume CT scanner is predominantly employed in the following areas: low dose scans of all body regions and organs (e.g. for diagnosis of accident victims and patients with multiple injuries); for complete diagnosis of heart and brain disease; and in angiography. It is also used for examinations of the face, paranasal sinuses, upper and lower jaw, temporal bones and dental CT. it is used in planning CT guided interventions, eg stenting of thoracic, abdominal and carotid arteries and neurological interventions; minimally invasive treatment of tumors as well as targeted pain therapies in the spine.

Dr. Waldeck and his Team are excited both by the new technology and the clinically advanced applications options. Examinations can now be performed with the Aquilion ONE / ViSION Edition, in which the balance between low dose and excellent image quality is standardized for all patients. The following examples show the added value that volume CT offers routine applications.

Case 1: Subarachnoid hemorrhage with hemorrhagic bifurcation aneurysm and acom aneurysm

A comatose patient was brought to the emergency room by emergency services. In a third-party anamnesis, the husband reported sudden extremely intense headaches and increasing disorientation.

The initial Brain CT in the emergency room detected a massive subarachnoid hemorrhage with ventricular rupture. The subsequently performed CTA revealed a large cerebral artery aneurysm in the area of the bifurcation, which was confirmed by invasive angiography and treated (Fig. 2). The platinum coils used in the treatment of such aneurysms are very susceptible to artefacts in conventional CTs due to the quantity of constituent metal. In particular, an assessment of the vessels and the immediate area, is thus, considerably more difficult or impossible (see Fig. 2: CCT without SEMAR vs. CCT with SEMAR in Fig. 2). The CTA scan was reconstructed with single energy metal artefact reduction (SEMAR) to reduce the artefact from the coils, enabling the contrast to be seen in the aneurysm (Fig. 2).

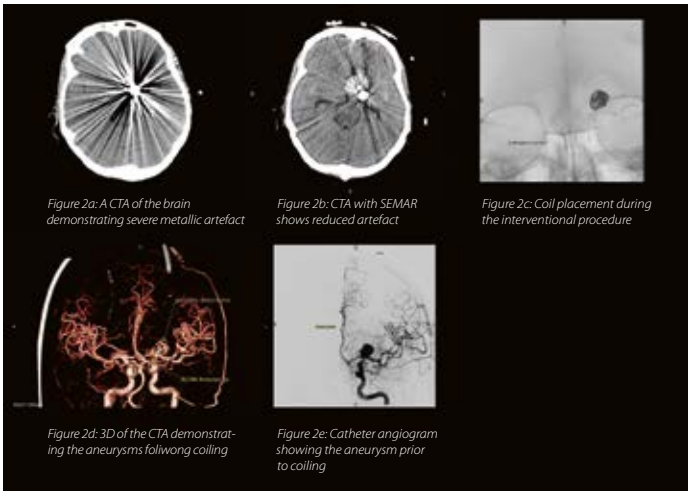

Figure 2a: A CTA of the brain demonstrating severe metallic artefact

Figure 2b: CTA with SEMAR shows reduced artefact

Figure 2c: Coil placement during the interventional procedure

Figure 2d: 3D of the CTA demonstrating the aneurysms foliwong coiling

Figure 2e: Catheter angiogram showing the aneurysm prior to coiling

The 16-cm detector width makes it possible, especially in cases involving such complex issues, to acquire highly-detailed vessel imaging and perfusion measurements in the shortest possible time. The new SEMAR technology also makes it possible to image vessels and cerebral parenchyma elements immediately adjacent to the coiled aneurysm in good diagnostic quality.

In particular, valid vessel imaging in cases involving interventionally- or surgically treated aneurysms was not previously possible with conventional devices due to the pronounced metallic artefacts and could only be performed by means of invasive catheter angiography. The combination of whole-brain perfusion with whole-brain angiography and optional artefact suppression (SEMAR), thus, represents an enormous diagnostic advantage.

[1] *Army Head Doctor, Head Doctor and Department Manager of the Viii Radiology Department, Armed Forces Central Hospital, Koblenz, Germany*

©2017 TOSHIBA MEDICAL

"The step from 64-slice to Aquilion ONE was more than a step forward."

Joost Roelofs

Lead radiographer CT
LUMC, Leiden, The Netherlands

As a lead radiographer Joost Roelofs has extensive, long-term experience in using Toshiba CT's including the Area Detector CT's. Starting with the Aquilion ONE™ and most recently the newly introduced Aquilion ONE™ GENESIS Edition.

1 How did you experience the introduction of the Aquilion ONE in your hospital?

We were the second hospital in Europe to get an Aquilion ONE. This scanner made it possible to carry out a number of new examinations and existing examinations will be of better quality and scanned much more quickly. This was illustrated by the fact that the trauma radiologist (Head of Department) was present at the receipt of a trauma patient during the first few days and stated that he had been in the profession for over 30 years and upon seeing this examination he had a "WOW" moment. The Head of the Cardiology Department was also present during the first cardiological examination carried out on the Aquilion ONE and his reaction was "OK, from now on, we are carrying out every cardiological examination using this scanner". In short, the step from 64-slice to Aquilion ONE was more than a step forward.

2 As training and education are a key aspect in your clinical environment, how did you handle training at your department when starting to use the Aquilion ONE?

We worked closely with the Toshiba Europe application specialists in order to train a starter group who then, in turn, trained the entire team (teach the teacher). As we received one of the first scanners, a great deal of discussion also took place with Toshiba Europe regarding the development of study protocols and scanning techniques (use of bolus triggering, dose modulation, image optimisation, etc.)

3 In day to day use, what advantages does the Aquilion ONE and Area Detector CT add to your clinical environment?

The major benefits are as follows: rapid acquisition times in paediatric examinations with lower doses, which means that sedation is often no longer required and immobilisation, with for example a vacuum cushion, is sufficient. The possibility of carrying out cerebral perfusion scans when receiving a patient who has had a stroke, which have also played a crucial role in the DUST trial and the MR CLEAN trial, for example. Organ perfusion, ECG-triggered aorta scans, etc. The result was that suddenly, the preference was to carry out a large number of examinations on the Aquilion ONE; therefore patients sometimes had to wait for one another.

4 How do you optimise and adjust protocols in your hospital?

The scan protocols are managed in our hospital by the CT expert, together with a small group of senior radiographers and, in terms of content, input is given by radiology staff (indications and phases/series to be scanned). The level of radiation exposure is tested by senior radiographers, who are supported by the group of clinical physicians. Management of the protocols in the scanner is carried out by the CT expert. Therefore, if a protocol needs to be optimised or introduced, then this is carried out by the aforementioned people.

5 How did you experience the evolution of Aquilion ONE to GENESIS? From both software as well as hardware point of view?

In the last 10 years, a number of applications have been developed further. These include improvements in possibilities within the field of cardiology (auto target, stress perfusion, better arrhythmia rejection, etc.)
What is more, the introduction of AIDR 3D resulted in a visible dose reduction. The GENESIS now has a faster rotation time, a higher tube potential, which means that more examinations can be carried out at 100 kV and, in combination with the iterative reconstructions and PUREViSION Optics, this also offers more options for dose reduction. Thanks to the area finder and the flared gantry design, it has become much faster and easier to scan extremities (wrists/elbows). And there are many more developments that we could mention.

6 Thinking out loud; what is your vision when it comes to the future of CT for the coming years?

The latest techniques such as FIRST reconstructions and SEMAR with helical scans will be calculated much more quickly in the future, which means that these techniques can be used as standard or in acute examinations. What is more, the number of CT examinations will continue to increase, including those carried out on children. This means that we need to remain critical of the level of radiation exposure and continue to reduce this as much as possible using new techniques and better hardware. In older patients, it is important to reduce the iodine dose as much as possible through even faster acquisition times, better iodine detection (by subtraction or dual energy or (virtual) monochromatic imaging techniques, for example) in order to limit any kidney damage.

©2017 TOSHIBA MEDICAL

Visit our CT Campaign webpage
www.toshiba-medical.eu/eu/ct-campaign-10-years-ahead
and download these digital CT articles from VISIONS 2007 – 2017!

Professor Mathias Prokop, Chairman of the Department of Radiology and Nuclear Medicine, Radboudumc

©2017 TOSHIBA MEDICAL

From Molecule to Man to Population

The Radboud university medical centre (Radboudumc) in Nijmegen, the Netherlands, aims to have a significant impact on healthcare with research spanning 'From Molecule to Man to Population'. With a team of more than 150 people , the Imaging Research group within the Department of Radiology and Nuclear Medicine develops imaging applications that bridge the gap between research and practice and help shape the future of healthcare. Professor Mathias Prokop, Chairman of the department, explains how the Aquilion ONE™ and close collaboration with Toshiba Medical's engineers in Japan and Europe over the last five years continue to enable the team to advance techniques in functional imaging.

Radboudumc purchased an Aquilion ONE in 2011 to advance research in functional imaging, recognizing the importance of this field for the future.

SYNERGY

"The market options available at the time meant that we could choose for speed (Dual Source CT scanners) or large coverage per rotation (Aquilion ONE). Functional imaging was in its infancy, so we expected to be able to impact the further development. We were looking for a partner and had a good click with Toshiba Medical," said Professor Prokop. "Before making a final decision, we visited the company's engineers in Japan, because we wanted to know how much they listened to users. I find that very important, because the field only moves forward if you get a good interaction between users and engineers. What we found out was impressive, and convinced us that working with Toshiba Medical was the way forward."

Since then, the collaboration has steadily grown. Radboudumc Imaging Research share their thoughts about the future with the engineers in Japan and co-develop in some areas. Regular meetings in Japan and Nijmegen ensure the continuity of discussions about ongoing projects and fine-tuning of the imaging systems currently in use at the hospital.

RAPID INTRODUCTION

Before installation of their new Aquilion ONE, Radboudumc planned the positioning of the new system strategically to ensure easy access and optimal flexibility for use by the Emergency Rooms and poli-clinics alike. Installation of the scanner went fast.

"We could use the system within a short period of time," said Professor Prokop. "Training went smoothly, although the interface was substantially different to those of the scanners that we had used before. Due to this, we first trained small groups of radiographers and expanded it to the rest, so that everyone felt comfortable."

EXPLORING NEW POSSIBILITIES

With the introduction of the Aquilion ONE, it became possible for the Radboudumc Imaging Research to collect functional together with morphological data. While employed for routine clinical practice, the Aquilion ONE allowed to continually explore new possibilities.

"The development of any new techniques starts with a vision that we initially evaluate. We see what is currently missing, and then approach Toshiba Medical to discuss what is needed to make things a reality. So far, this has gone very well," explained Professor Prokop. "Toshiba Medical also implements our feedback on optimization into new software. I have been amazed by the speed at which the feedback is implemented."

The brain is a classic region for testing a lot of new techniques in radiology. Brain perfusion imaging (CTP) using the Aquilion ONE was introduced early on and is used in addition to a pre-contrast CT and CTA for the evaluation of stroke. "With full brain coverage provided by Aquilion ONE, we can investigate stroke outside the classical field around the basal ganglia," said Professor Prokop. "Perfusion with the Aquilion ONE gives us a higher detection rate of vascular occlusions, even in peripheral branches. Malperfused regions indicate areas that we need to return to in order to look for occlusions. CTP is easy to set up, works quite rapidly and doesn't delay our clinical process."

"Our ultimate goal for CT imaging of stroke, however, is to eliminate the CTA and pre-contrast scan and rely on CTP only. A prerequisite is that the information from CTA and pre-contrast CT can be extracted from a single CTP sequence. In the past years we have developed and optimized such techniques. As a result, we now can reduce overall examination time, the amount of iodinated contrast and the overall radiation dose."

DEVELOPING NEW TECHNIQUES

In their quest for optimum use of CTP, Radboudumc Imaging Research have been developing an interesting technique for a subset of particularly vulnerable patients. The One-Step-Stroke protocol, a single examination sequence, in which the neck CTA is interleaved with CTP. One-Step-Stroke imaging has the potential to replace a separate CTA, which saves radiation dose and contrast agent dose. It can reduce the amount of contrast required by almost half ([1], [2]).

"The nice thing about this technique is that it doesn't affect the qualitative perfusion values," said Professor Prokop."In addition, it acts as bolus triggering for CT perfusion: in a patient with delayed contrast arrival, a 60-second acquisition can stop too early before the contrast is optimally distributed. The One-Step-Stroke protocol interrupts the standard CTP sequence for a wide volume CTA of the neck and then returns to the brain, where a fixed amount of scans (e.g. 20) is performed after the contrast has arrived, which ensures constant CTP quality and avoids truncation artifacts."

"We are currently exploring combining the wide volume CTA of the neck with subtraction; performing an initial pre-contrast scan, followed by the One-Step-Stroke technique, and finally subtracting in the neck region to gain vessel-only CTA. This substantially reduces scatter artifacts in the shoulder region," he added.

OPPORTUNITIES TO ADVANCE EXISTING APPLICATIONS

The Aquilion ONE as well as the Aquilion ONE ViSION Edition and Aquilion ONE GENESIS Edition offer full flexibility in planning scan protocols, which makes them ideal for perfusion studies.

"You can chose continuous volumetric scanning for high temporal resolution, which results in 4D data that overlaps in the time domain," said Professor Prokop. "We do that in patients with arteriovenous (AV) malformations to find the nidus, for example. You can also perform a set of rapid volumetric scans in the early phase of enhancement, followed by longer time delays between scans in later phases, and you can also change the amount of dose that you give for each of these phases."

The flexibility of Toshiba's area detector CTs makes it possible to develop unique protocols that combine the advantages of regular abdominal examinations with those of CT perfusion. "A diagnostic scan interleaved with a perfusion scan gives the best of two worlds - That's possible on this scanner," he added.

Transferring new techniques like these to clinicians so that they understand the full implications of opportunities can be challenging. For the best results, Radboudumc pairs pre-clinical researchers with radiologist, who explore this together with their clinical partners.

Professor Prokop's dream for the future is to use CT perfusion for many of the indications that currently require a multiphasic CT. However, he admits that many prerequisites must be fulfilled before that will be possible.

"We have recently joined forces with Toshiba Medical's engineers to develop a very potent noise reduction algorithm that enables high resolution CT perfusion imaging, at a much higher resolution than we can achieve at the moment. It also allows us to do excellent 4D analysis of the vasculature in the region of interest. It is an essential step forward," he remarked. "We hope to see our noise reduction algorithm introduced in mid-2017. It's a very powerful tool that we think will become a 'game changer'. When transferring this to other areas of the body, such as the lungs or abdomen; motion correction becomes a key factor. The Aquilion ONE scanners already have great motion correction in the abdomen and lung, which is good for subtraction imaging, but we are working to improve it further to create a totally new image quality."

SUBTRACTION

"We are really happy with the subtraction technique for the Aquilion ONE scanners. It's very versatile. We have used it routinely for pulmonary angiographs for more than two years. In the lung, it helps us find perfusion defects, which we then examine further; the enhancement of nodules; and areas of infection or active inflammation," he said."One of the big advantages SUREsubtraction is that you get a much better signal at a lower noise - around 40-50% less noise - than with Dual Energy CT scanning techniques. We believe that subtraction will be very important in the future."

"I would, however, like to see even better image registration for the lung that enables not only the lung parenchyma, but also the vessels, to be registered perfectly or almost perfectly," he continued. "We can then use that information for many different things, like being able to reduce the amount of contrast administered by virtually increasing contrast enhancement - similar to virtual monoenergetic images from Dual Energy CT. We can create these images by adding the enhancement from the subtraction image onto the original contrast-enhanced images and combining this with noise reduction. Toshiba Medical has already implemented the first step of this in the abdomen and we hope to see it in other areas of the body in the future."

PIVOTAL IN THE FUTURE

Over the next decades, Professor Prokop anticipates that radiology, and medicine in general, will become far more

©2017 TOSHIBA MEDICAL

Professor Mathias Prokop is one of the world's leading experts on body imaging. With a particular interest in new CT technologies, he has explored the boundaries of this modality for the last 30 years, and led many research efforts worldwide

computer-supported, with a great deal of routine work automated and accelerated, so that the role of radiologists becomes more consultancy-based than focused on pure high throughput. For CT, he believes that spatial resolution could improve further in the coming years, but finally will be limited. And that the biggest focus will be on software development. In addition, he thinks that the introduction of photon counting detectors will make it possible to further optimize functional imaging, but will take a while to emerge.

"Streamlining our workflows will be supremely important and will help us make the right decisions. High-end imagining techniques will be pivotal in this," he concluded.

References:

1. M.T.H. Oei, F.J. Meijer, W.-J. van der Woude, E.J. Smit, B. van Ginneken, M. Prokop and R. Manniesing. "Interleaving Cerebral CT Perfusion with Neck CT Angiography. Part I: Proof of Concept and Accuracy of Cerebral Perfusion Values", European Radiology.
2. M.T.H. Oei, F.J. Meijer, W.-J. van der Woude, E.J. Smit, B. van Ginneken, R. Manniesing and M. Prokop. "Interleaving Cerebral CT Perfusion with Neck CT Angiography. Part II: Clinical Implementation and Image Quality", European Radiology.

"We are now able to perform cardiac examinations very easily, they are not time consuming anymore."

1 What where your expectations at the time of installation of the Area Detector CT?

We expected to have a reliable partner for clinical routine. Furthermore we expected to have robust and convenient material to work with.

2 How did you experience the introduction of the Aquilion ONE in your hospital?

We experienced the introduction of the Aquilion ONE™ quite well. Only thing was that we experienced some technical problems with the detector immediately after the installation but these were resolved easily

3 How has the installation of the Aquilion ONE changed your daily clinical practice?

We are now able to perform cardiac examinations very easily, they are not time consuming anymore. Other than that we have found that vascular diseases can be well evaluated except for the lower limbs where we see that the distal part become difficult to visualize.

4 What has been the influence of the Aquilion ONE and Area Detector CT in patient management?

We have found that all the Cardiac applications are now being used in our clinical routine.

5 Have you been able to accept a wider variety of patients after the introduction of the Area Detector CT?

We did not encounter a wider variety of patients being scanned but we did notice that the scanner is always overbooked. It is therefor always open, 24 hours per day, 7 days a week.

6 How do you use the 16 cm Z-axis coverage in daily clinical routine? And how did this affect radiation dose and contrast dose used in your clinic?

Used in routine for cardiac, TAVI, renal perfusion and to obtain a dose reduction in abdominal exploration for oncologic patients (especially young patients)

7 How has the visualization of Kidney pathology changed with the availability of the Area Detector CT?

The use of the Area Detector CT provides us with better functional information due to the perfusion studies we perform.

8 You have also been very active regarding Kidney Perfusion in CT, what will be the next step in CT Kidney Perfusion to your opinion?

To evaluate the treatment in oncologic patients and perhaps to evaluate the renal functional (instead of scintigraphic exploration). The radiation dose additionally should come down to even more acceptable levels.

9 What role do you see for Perfusion CT in general for the future?

Please find the answer above in the previous question.

10 Thinking out loud; what is your vision when it comes to the future of CT for the coming years?

Reduction in the use of iodinated contrast thanks to Auto kV and further reduction of radiation dose with improved iterative reconstruction techniques.
Additionally an improvement for the speed of the reconstruction and presentations of the clinical images.
Finally we see the development of more convenient software to compare data between different examinations.

Prof. C. Roy

Professor of Radiology
University Hospital
Strasbourg, Strasbourg,
France

Prof. C. Roy and her team in Strasbourg have worked in many different areas using Toshiba Medical's Area Detector technique. Ranging from the use of Wide Volume scanning for dose reduction, optimization of TAVI scans and kidney perfusion.

CTEU160128 ©2017 TOSHIBA MEDICAL SYSTEMS

Coronary Subtraction, CT Angiography, Coronary Artery Disease

CTEU140095

DOWNLOAD THE FULL ARTICLE ON:
www.toshiba-medical.eu/eu/ct-campaign-10-years-ahead

First Clinical Results of Coronary CT Subtraction

D. Viladés-Medel MD [1,2], R. Leta MD[1,2], A. Hidalgo MD PhD [1,2], F. Carreras MD PhD [1,2], G. Pons-Lladó MD PhD [1,2], X. Alomar MD [1]

Computed Tomography Angiography (CTA) of the coronary arteries is a useful non-invasive tool to rule out significant Coronary Artery Disease (CAD) in many clinical situations. Recent guidelines of stable CAD[1] and non-ST segment elevation myocardial infarction[2] endorse the use of CTA in symptomatic patients with low to intermediate likelihood of the disease, given the particularly high negative predictive value of the technique. However, in patients with high pre-test likelihood of CAD, the technique is not recommended, and one of the reasons is the high probability of coronary calcification in these patients, which interferes with the analysis of the images and reduces the specificity and negative predictive value of CTA[3-6].

CLINICAL CASE EXAMPLE

69 year-old male, past smoker with hypertension and moderate chronic renal failure with a glomerular filtration rate of 40 mL/kg/min. No previous cardiac history. During the last weeks he presented with atypical chest pain and an inconclusive exercise ECG (subtle changes in cardiac repolarization without associated angina).

Cardiac computed tomography angiography (CTA) showed high degree of calcification in left anterior descending artery that impeded the assessment of the wall lumen in these segments (Agatston score 845) (figure A). After cardiac subtraction we could observe a vessel without any significant lesion (figure B) also proven at an invasive coronary angiography (figure C).

Conclusion: The Toshiba Coronary Subtraction application is a promising tool to minimize calcium and metallic artefacts, as this clinical case has exemplified. Coronary calcium subtraction may improve the diagnostic accuracy of CTA, especially in those patients with extensive calcifications or small stents. More studies are needed to validate this diagnostic tool and find out what role this could have in clinical practice.

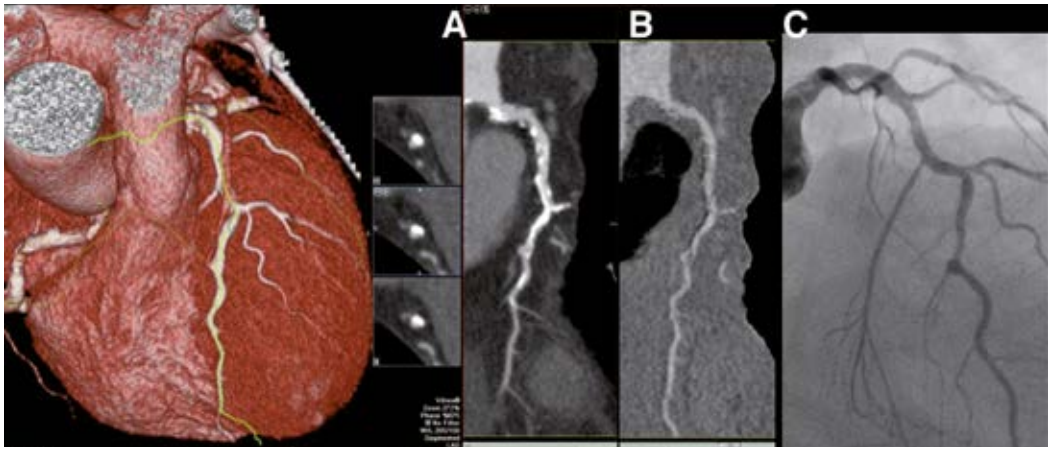

1. Members TF, Montalescot G, Sechtem U, Achenbach S, Andreotti F, Arden C, et al. 2013 ESC guidelines on the management of stable coronary artery disease: The Task Force on the management of stable coronary artery disease of the European Society of Cardiology . Eur Hear J 2013;34 (38):2949–3003.
2. Hamm CW, Bassand J-P, Agewall S, Bax J, Boersma E, Bueno H, et al. ESC Guidelines for the management of acute coronary syndromes in patients presenting without persistent ST-segment elevation: The Task Force for the management of acute coronary syndromes (ACS) in patients presenting without persistent ST-segment elevation of the European Society of Cardiology (ESC) . Eur Hear J 2011;32 (23):2999–3054.
3. Stolzmann P, Scheffel H, Leschka S, Plass A, Baumüller S, Marincek B, et al. Influence of Calcifications on Diagnostic Accuracy of Coronary CT Angiography Using Prospective ECG Triggering. Am J Roentgenol. 2008;191(6):1684–9.
4. Vavere AL, Arbab-Zadeh A, Rochitte CE, Dewey M, Niinuma H, Gottlieb I, et al. Coronary Artery Stenoses: Accuracy of 64–Detector Row CT Angiography in Segments with Mild, Moderate, or Severe Calcification—A Subanalysis of the CORE-64 Trial. Radiology 2011;261(1):100–8.
5. Abdulla J, Pedersen KS, Budoff M, Kofoed KF. Influence of coronary calcification on the diagnostic accuracy of 64-slice computed tomography coronary angiography: a systematic review and meta-analysis. Int J Cardiovasc Imaging. 2012;28(4):943–53.
6. Meijboom WB, van Mieghem C a G, Mollet NR, Pugliese F, Weustink AC, van Pelt N, et al. 64-Slice Computed Tomography Coronary Angiography in Patients With High, Intermediate, or Low Pretest Probability of Significant Coronary Artery Disease. J Am Coll Cardiol. 2007;50(15):1469–75.

[1] *Clinica Creu Blanca, Barcelona*
[2] *Unitat d'Imatge Cardíaca Hospital de Sant Creu i Sant Pau Spain*

"Working with an Area Detector CT has allowed us to increase the indications of the Cardiac CT to patients with greater complexity that previously would not have been able to opt for this technique."

Dr. David Viladés Medel

Cardiologist at Clinica Creu Blanca, Barcelona and Unitat d'Imatge Cardiaca Hospital de Sant Creu I Sant Pau Spain

Dr. Viladés Medel, Dr. Leta Petracca and Dr. Alomar have been very active in Coronary CTA imaging. As leading experts in Coronary CTA they have published extensively using Toshiba Medical's Area Detector CT. They continuously push boundaries and strive for the best IQ in all their patients ranging from CCTA and perfusion to Coronary Subtraction.

1 What where your expectations at the time of installation of the Area Detector CT?

We thought it would help us to expand Cardiac CT to enable investigation of more complex clinical scenarios.

2 How did you experience the introduction of the Aquilion ONE™ and later the Aquilion ONE ViSION Edition in your hospital?

Our experience was favorable and covered several of our expectations

3 How has the installation of the Aquilion ONE changed your daily clinical practice?

Being able to acquire the majority of cardiac studies in a prospective way (and in a single beat) has brought about a radical change in the way that we work.

4 Your Department covers a wide range of patients. How have the Aquilion ONE and Area Detector CT influenced patient management for you?

As previously mentioned, working with a Area Detector CT has allowed us to increase examinations of Cardiac CT to include patients with indications of greater complexity that previously would not have been able to opt for this technique: patients with the inability to perform prolonged breath-holds (limited indication in conventional helical cardiac CT studies), patients with severe coronary calcification, etc..

5 How has the introduction of the Area Detector CT opened doors to new ways of imaging in your department?

This type of technology has allowed us to extend the indications of the technique to patients with high pre-test coronary risk, as well as patients with established ischemic heart disease (nowadays, with very limited indication in the guidelines of current practice).

6 You and your colleagues have recently published a paper in European Radiology about the use of SUREsubtraction Coronary, in which you have found an improvement of image quality when using this subtraction method. How do you use this technique in your clinical routine now?

We acquire these examinations in a single breath-hold after observing a significant reduction of misreading artifacts and an improvement in image quality. This type of examination has allowed us to gain precision in the assessment of the magnitude of

©2017 TOSHIBA MEDICAL

Dr. Xavier Alomar

Head of the Radiology Department at Clinica Creu Blanca, Barcelona

Dr. Rubén Leta Petracca

Cardiologist at Clinica Creu Blanca, Barcelona and Unitat d'Imatge Cardiaca Hospital de Sant Creu I Sant Pau Spain

established coronary disease, as well as the assessment of metal stents (regardless of their size and composition). In our previously mentioned study, we obtained a good anatomical correlation in these clinical scenarios in comparison to invasive coronary angiography.

7 What is your opinion on CT FFR and its (future) role in Cardiac CT?

Invasive FFR is now the gold-standard technique in the functional assessment of coronary lesions. With this in mind, we believe that any non-invasive tool that provides the same information is a milestone in the world of Cardiac CT. Being able to obtain this information in your workstation (within a few minutes) and by adding this information to the excellent anatomical image converts Cardiac CT into a complete technique for patient management, without requirement for other additional non-invasive modalities. This could bring greater comfort to patients by reducing the time required for an accurate diagnosis and, thus, enabling therapy to be established in the shortest time possible.

8 You have a lot of experience with Cardiac CT. How do you optimize your protocols and the CT acquisition according to your patient population?

We optimize cardiac CT in these three clinical scenarios:

- Asymptomatic patient (for screening purposes): Low dose is crucial (narrow window of acquisition, lowest possible kilo voltage and the best iterative reconstruction protocol).
- Symptomatic patients with low- to intermediate probability of coronary artery disease: Window of acquisition is broader, sometimes acquiring the whole beat, which also allows us to obtain functional ventricular information that has a prognostic impact for the patient.
- Symptomatic patient with previous coronary artery disease: Acquisition in a single breath-hold of two volumes: one without contrast, and one second with contrast, that allow us to perform a cardiac calcium and also metal stent subtraction, given the high pre-test probability of having coronary artery calcification. If the patient has intermediate or significant coronary artery lesions, we perform a functional assessment of myocardial perfusion with cardiac stress MRI. As previously discussed, if a robust CT-FFR was available, this second study would probably not be necessary for this purpose.

9 What is your vision when it comes to the future of CT for the coming years?

For the future, we asked for a CT with better temporal resolution (crucial) that would lead to an improvement in accuracy with less motion artifacts and misreading of artifacts in other techniques, such as cardiac calcium subtraction. We also asked for greater spatial resolution for more accurate assessment of coronary plaque atheroma (plaque volume and its composition) to improve the evaluation of coronary artery disease progression. This is important for the follow-up of asymptomatic patient populations, as well as to ensure the lowest dose as possible for these kinds of patients. Related to this, an improvement in the software of the workstations is necessary that allows us to work side-by side and compare two examinations (of the same patient) acquired in different moments.

TOSHIBA MEDICAL

Together, we complete the image.

Made For life

Toshiba Medical is rearming its commitment to its Made for Life philosophy and launching a new theme and advertising campaign called "Together, we complete the image".

This campaign supports our Made for Life philosophy by focusing on our tradition of customer collaboration, developing products that are made for clinicians, patients and partnerships.

At Toshiba Medical, we listen to customers to truly understand their needs in imaging and beyond. Our goal is to work hand-in-hand with our partners to deliver flexible solutions that not only meet their needs but deliver optimal health opportunities for patients.

Together, we save time.

Toshiba Medical Celebrates 10 Years of Area Detector CT

Described as 'a breakthrough CT system' back in 2007, Toshiba Medical introduced the world's very first dynamic volume CT scanner, The Aquilion ONE™. Driven by the clinical need for a volume scanner, the Aquilion ONE's unique Area Detector opened doors to new ways of medical imaging. Ten years later, Toshiba Medical is celebrating this memorable introduction!

This VISIONS Special highlights personal experiences of Key Opinion Leaders. It outlines Toshiba Medical's journey in Area Detector CT and shows our continuing spirit to explore the unknown.

To download the digital version of this CT Special, visit:
www.toshiba-medical.eu/eu/ct-campaign-10-years-ahead

To stay up to date with our latest innovations in medical imaging, visit:
www.toshiba-medical.eu

10
YEARS AHEAD
Area Detector CT